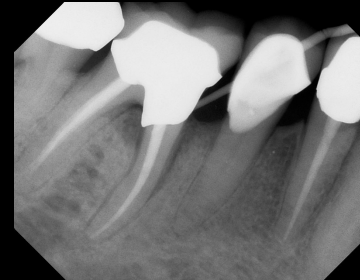
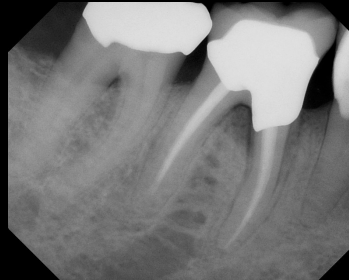
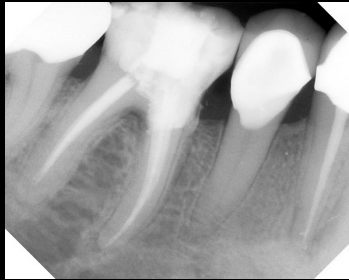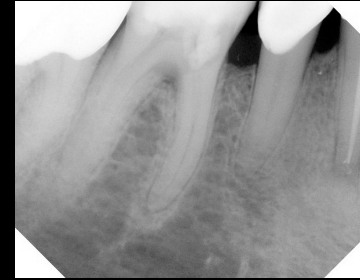Minimizing the Heartbreak of Split Teeth and Fractures

Sacramento District Dental Society Midwinter Convention 3/26/2026



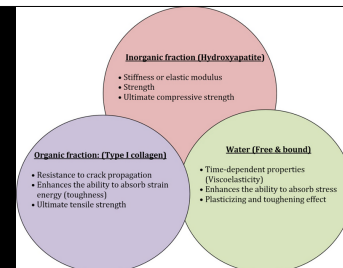
Longitudinal Tooth Fractures

- Craze lines
- Fractured cusp
- Cracked tooth
- Split tooth
- Vertical root fracture

Longitudinal tooth fractures: findings that contribute to complex endodontic diagnoses
ERIC M. RIVERA & RICHARD E. WALTON, 2007
18 (1) 84-111

Endodontic Topics

Dentin Properties



Endodontic Topics

Kishen, A. (2015). Biomechanics of Fractures in endodontically treated teeth. Endod Topics, 33: 3-13. doi:10.1111/etp.12089

Dentinal Tubule Changes

- Decreases apically
- Most dense toward pulp
- Largest diameter toward pulp
- Increase in mineral content toward pulp

Mantel Dentin

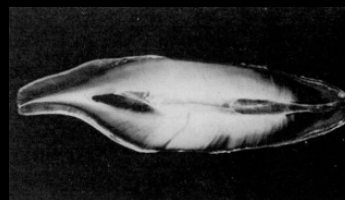
- First layer under enamel
- Hypomineralized
- Important in "resilience zone"

Varying Strength of Dentin

- Dentin is anisotropic with best strength resisting perpendicular forces
- Deep dentin of the crown is weaker than superficial dentin

Transparent Dentin

- Increases with age
- Is present apically
- Has almost no yielding before fracture
- Is more prominent in root filled teeth



Endodontic Topics

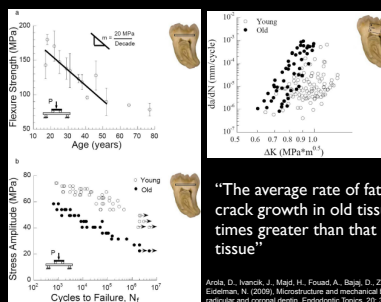
Tajderhane, L., Carrilho, M. R., Breschi, L., Tay, F. R. and Pashley, D. H. (2009). Dentin basic structure and composition—an overview. Endodontic Topics, 20, 3-29.

“The evidence is that age-related microstructural changes could cause a reduction in the UTS of radicular dentin”

Arora, D., Ivanick, J., Majd, H., Fouad, A., Bajaj, D., Zhang, X.-Y. and Esfahani, N. (2009). Microstructure and mechanical behavior of radicular and coronal dentin. Endodontic Topics, 20, 30-51.

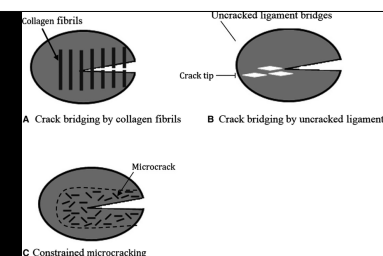
Dentin Aging

- Coronal dentin becomes more brittle
- Flexural strength is reduced an average of 20MPa per decade
- Energy required to produce fracture is reduced
- Dentin from tooth of person over 55 is 50% as strong and has a 75% reduction energy required to produce fracture



“The average rate of fatigue crack growth in old tissue is 100 times greater than that of young tissue”

Arora, D., Ivanick, J., Majd, H., Fouad, A., Bajaj, D., Zhang, X.-Y. and Esfahani, N. (2009). Microstructure and mechanical behavior of radicular and coronal dentin. Endodontic Topics, 20, 30-51.



Endodontic Topics

Krishan, A. (2015). Biomechanics of fractures in endodontically treated teeth. Endod Topics, 33, 3-13. doi:10.1111/ep.12089

“Endodontically Treated Teeth Do Not Become More Brittle”

?

Endodontic Topics
Arita O, Hanzek, A, Maki N, Fildes A, Biji D, Zhang X, Y, and Eldeman, N. (2009), Microstructure and mechanical behavior of radicular and coronal dentin. Endodontic Topics, 20: 30-51.

Water and dentin

- Intrapulpal pressure of 10-28mm Hg
- Water is bound to collagen
- Water has a hydraulic cushioning effect
- Hydrated dentin has significantly higher crack initiation and crack growth toughness

Arch Position

- Anterior teeth can splay forward during loading
- More vertical force is generated closer to hinge axis
- Posterior teeth absorb more vertical force an

Existing Tooth Structure

- Occlusal cavity preparation reduces stiffness by 20%
- MOD reduces stiffness by 83%
- Endodontic access reduced stiffness by 5%

Decreased Prognosis in High Transverse Functional Loads

- Not predictable in distal extension partial dentures, precision attachments, or cantilever FPD
- May not be suitable abutments in bruxism or long span FPD

Cuspal Inclination and Cracked Teeth

- Steeper cuspal incline concentrates stress on the mesial distal groove
- Load on non-functional cusps

Dental Traumatology

Glan, Y., Zhou, X. and Yang, J. (2013), Correlation between cuspal inclination and tooth cracked syndrome: a three-dimensional reconstruction measurement and finite element analysis. Dental Traumatology, 29: 226-231.

Pericervical Dentin

- Dentin 4mm below and 4mm above the alveolar crest
- Critical for ferrule and resistance to fracture
- Weakening in this area has profound impact on long term retention

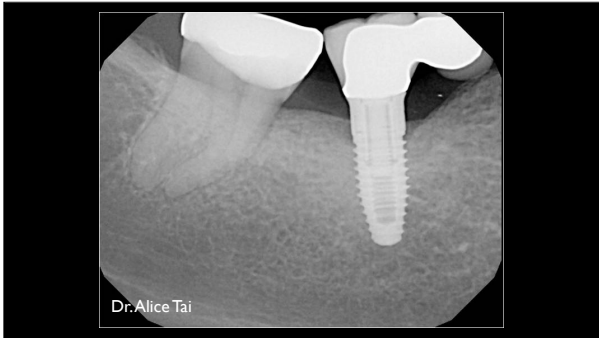
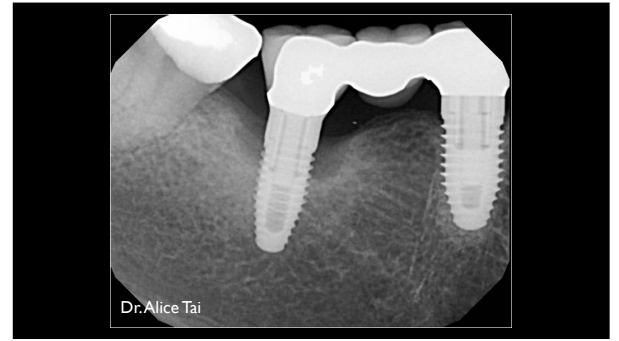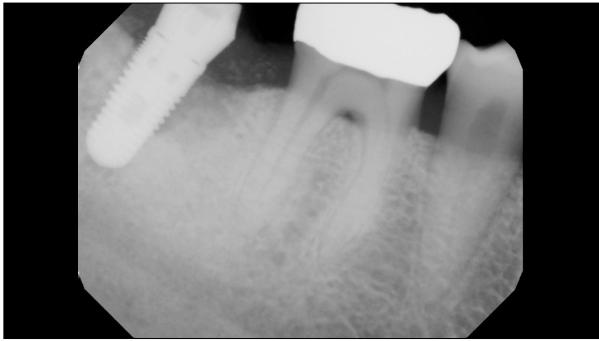
Occlusal Risk Factors

“Conclusion
Although the etiology of NCCLs is considered to be multifactorial, the findings of this study indicate that the direction and intensity of the forces applied on teeth are important contributors to the occurrence of NCCLs.”

Journal of Prosthetic Dentistry
Clinical evaluation of the association between noncarious cervical lesions and occlusal forces. Scintilla A, Bramante, Cristina, Luperdi, Tevian, Sonia Regina Panzani, Denise Podina. Journal of Prosthetic Dentistry - November 2012 (Vol. 108, Issue 5, Pages 288-303)

Predisposing Factors

- Tooth type: Maxillary premolars and mandibular molars (2nd)
- Extensive loss of dentin
- Marginal ridges absent
- Bruxism
- Collagen alteration (dehydration, microbe induced)



Endodontic Topics Kishen, A. (2015). Biomechanics of fractures in endodontically treated teeth. *Endod Topics*, 33: 3-13. doi:10.1111/etp.12089

- Slightly truncated proximal and occlusal walls
- Rounded line angles
- Flat gingival floor
- Smooth and flowing
- 330 carbide or diamond ideal for prepping this design
- Optimal treatment of enamel rods
- No bevels

Exit Angles

#30 M Box-only Fill

Diagnosis

Cracked tooth

- Mesio-distal direction
- Coronal to apical progression

Vertical root fracture

- Bucco-lingual direction
- Apical to coronal progression

History

- Time component from treatment
- Protracted symptoms
- Initial diagnosis was difficult
- Minimally restored dentition

Cracked Tooth

- Pain on mastication (especially release)
- Variable pulpal responses
- Tend to be more chronic
- Normal radiograph (cone beam?)

Fractured Cusp

- Pain to biting (tooth slooth)
- Temperature hypersensitivity
- Normal radiograph
- Normal periapical
- Remove mobile segment
- Cuspal coverage

Longitudinal tooth fractures: findings that contribute to complex endodontic diagnoses ERIC M. RIVERA & RICHARD E. WALTON. 2007 16 (1) 84-111

Endodontic Topics

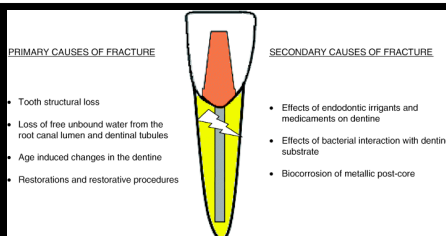
Diagnosing Fractures

- Often years after endodontic and prosthetic procedures completed
- Diagnosis usually involves differential
- Only treatment option is extraction



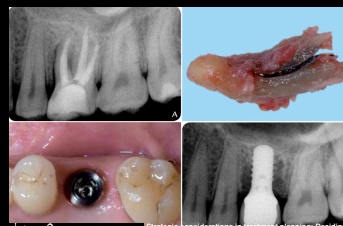
Vertical root fractures in endodontically treated teeth: diagnostic signs and clinical management. AVIAD TAMS. 2006: 13 (1) 84-94

Endodontic Topics



Endodontic Topics
Mechanisms and risk factors for fracture predilection in endodontically treated teeth
ANIL KISHEN. 2006: 31 (1) 57-63

Endodontic risk factors

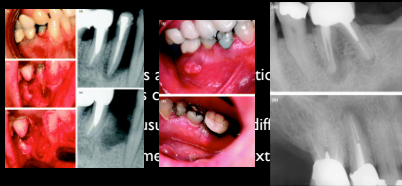


Strategic considerations in treatment planning: Deciding when to treat, versus to replace a questionable tooth Nicola J. Zermani, Catherine Moroni, Harjo Hecker, Camilla Walter, Tuomas Waltimo, Roland Weiger. Journal of Prosthetic Dentistry. August 2010 (Vol. 104, Issue 2, Pages 89-9)

Radiographic features

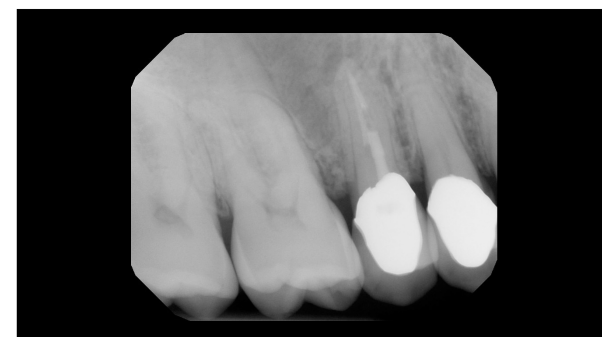
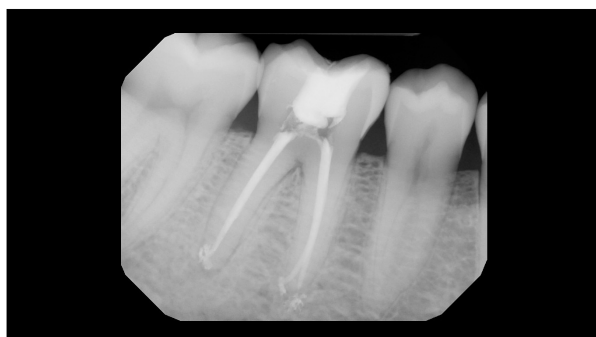
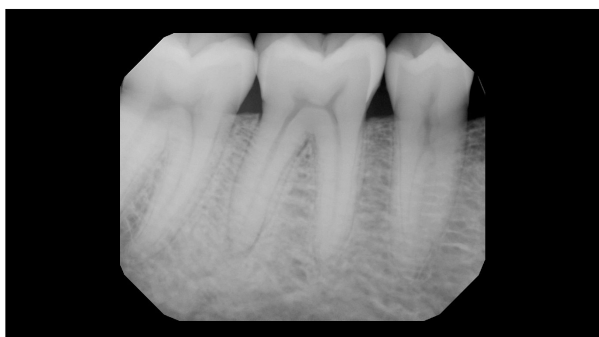
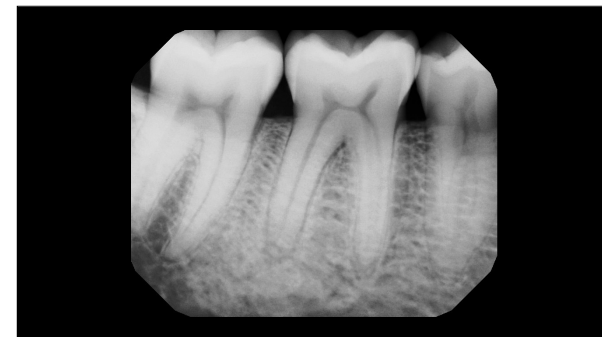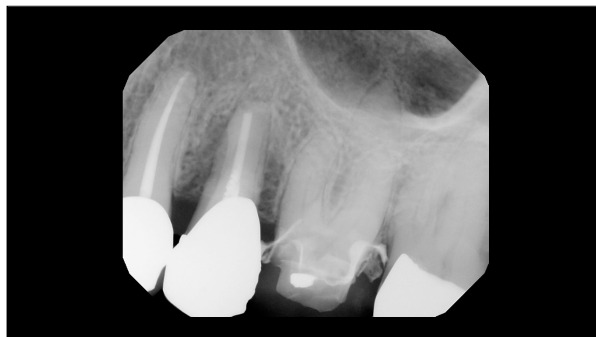
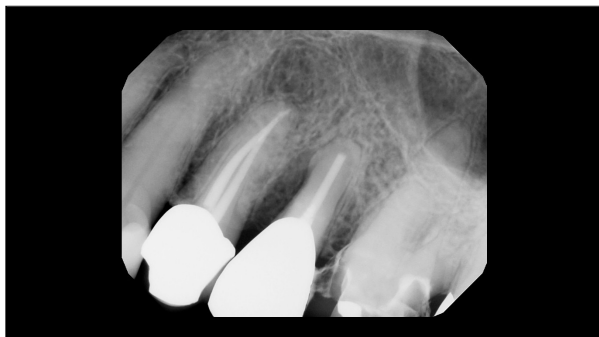
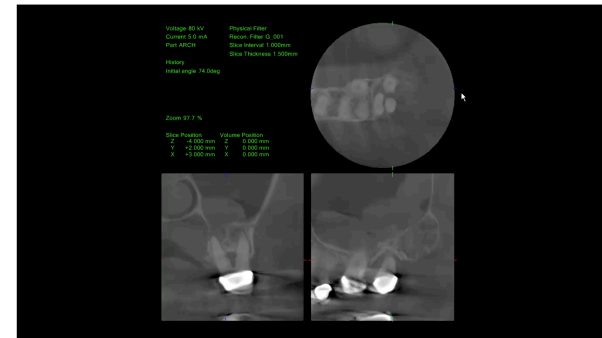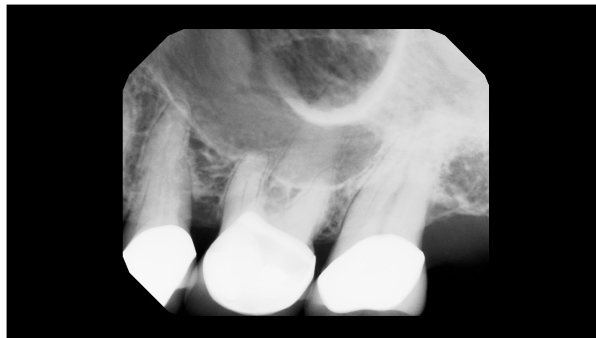- "Halo" or "J" shaped radiolucency
- "Adequate" endodontic treatment

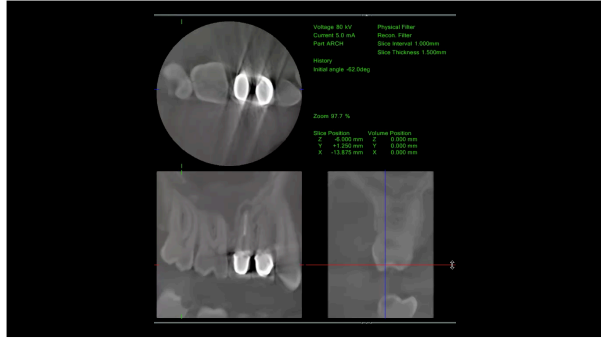
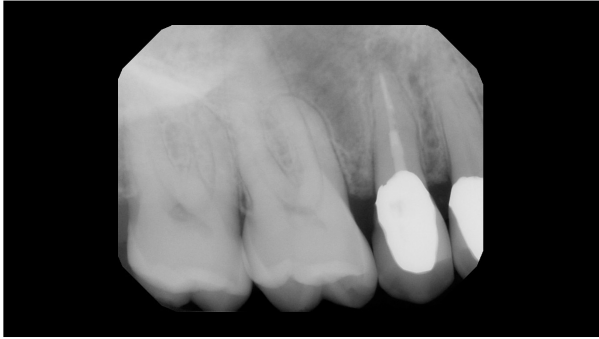
Bone Loss Pattern



Vertical root fractures in endodontically treated teeth: diagnostic signs and clinical management. AVJAD TAMS 2008. 13 (1) 84-94

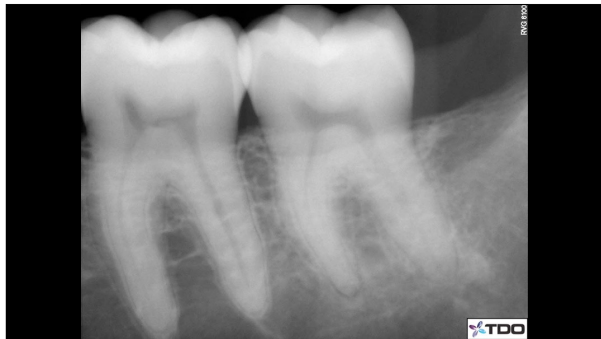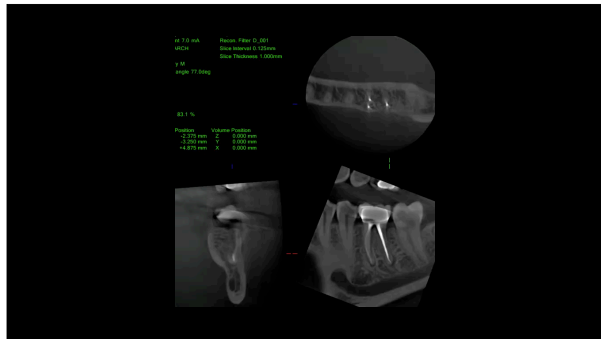
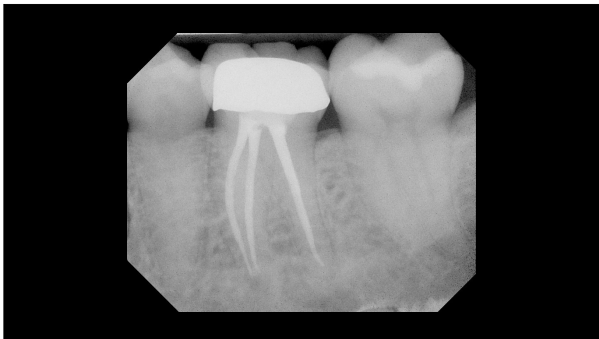
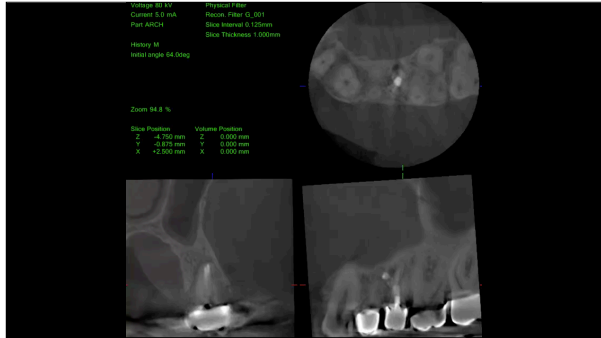
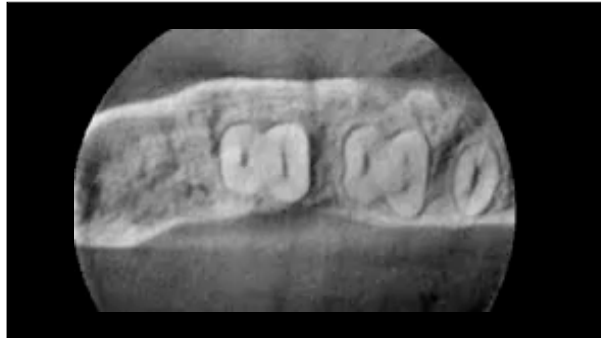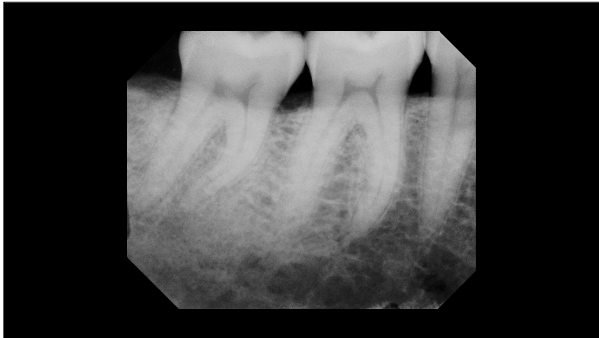
Endodontic Topics

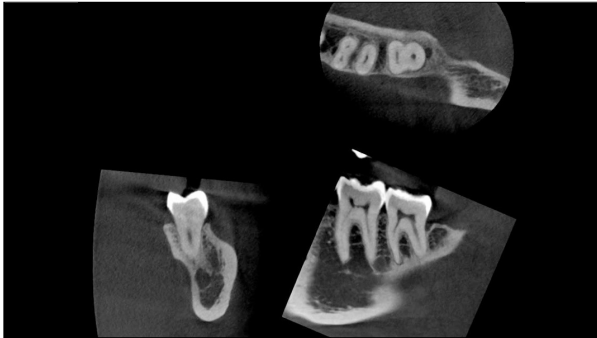
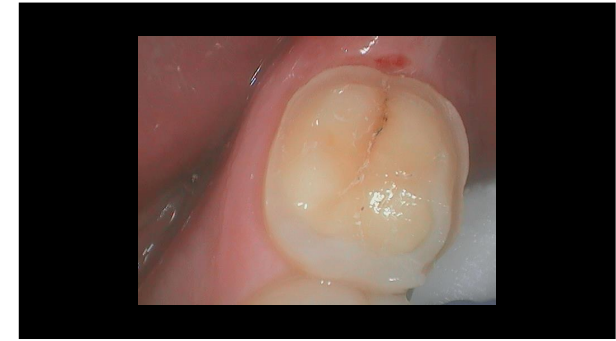
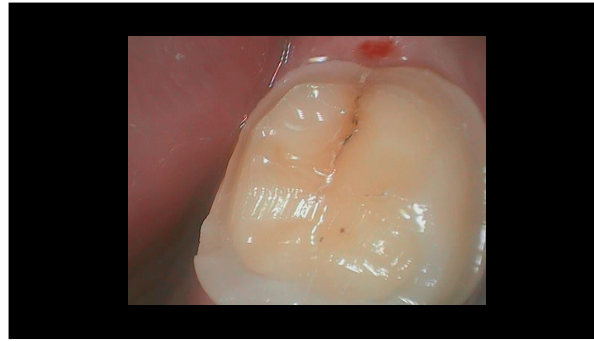
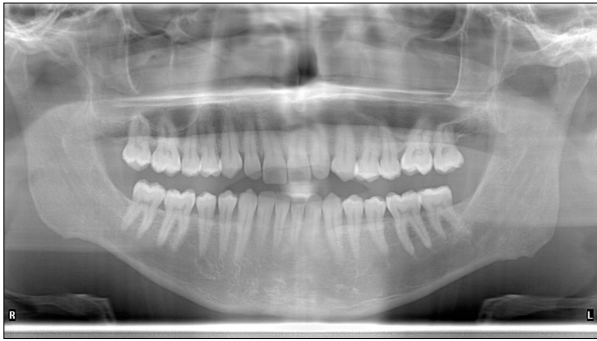

Interpreting CBCT Image

- Biologic evidence of bone loss
- Vital pulp increases probability



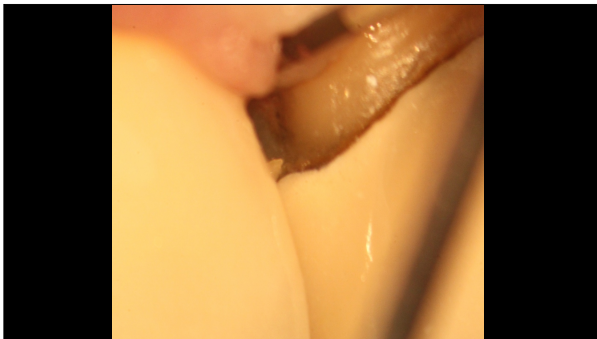

Clinical Exam

- Signs of parafunction
- Often minimally restored
- Magnification of dentin at gingival margin
- Isolated periodontal defect (often under contact)

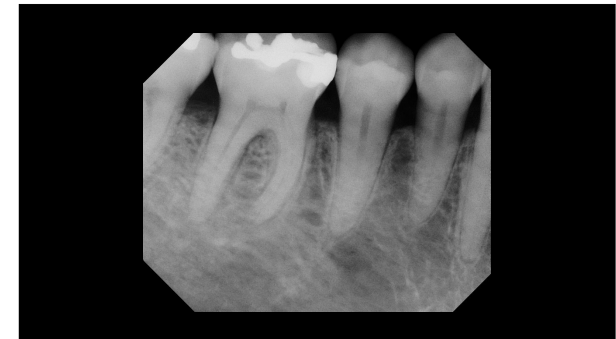Visualization

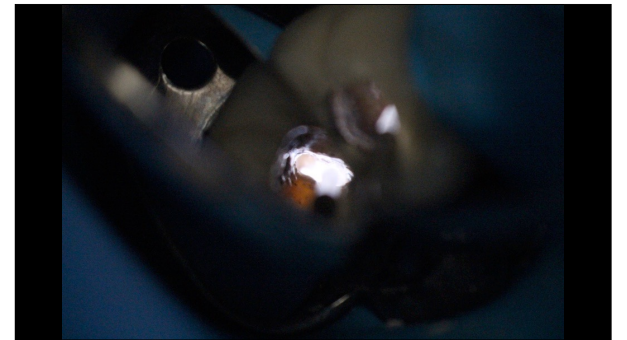
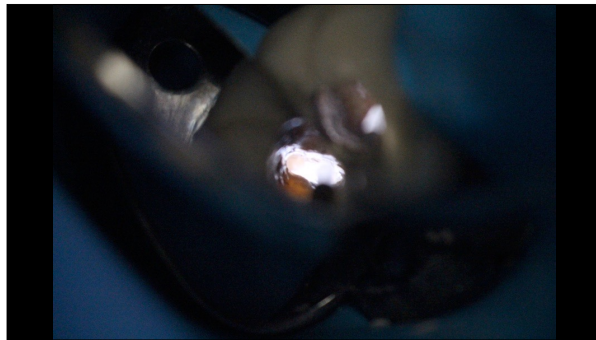
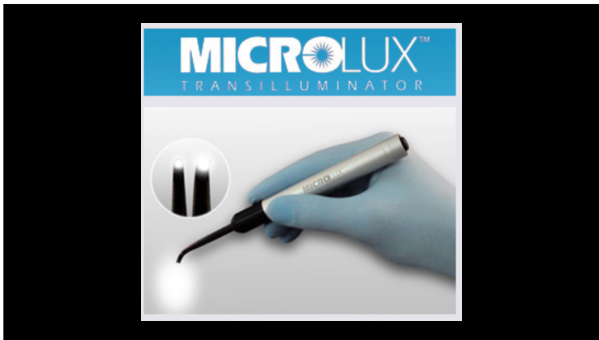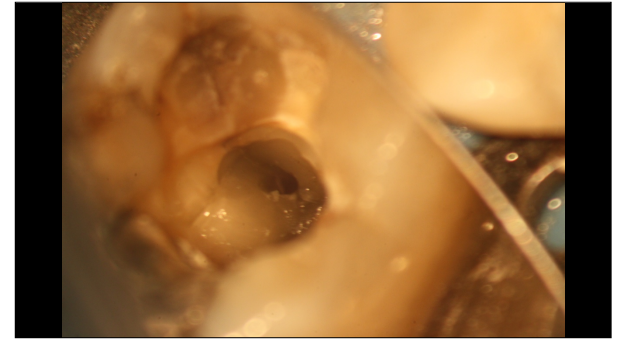
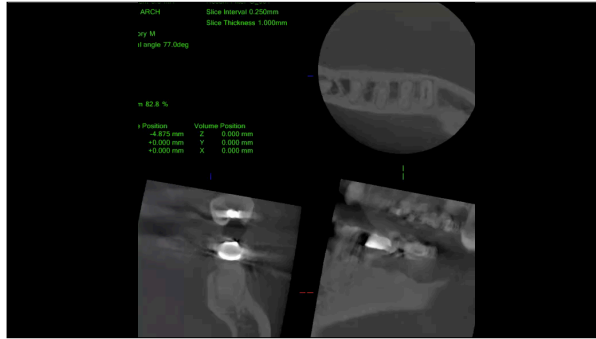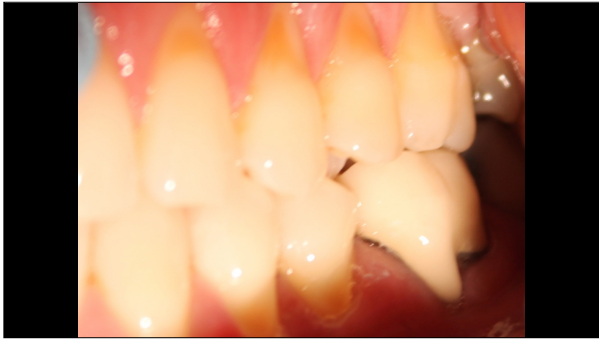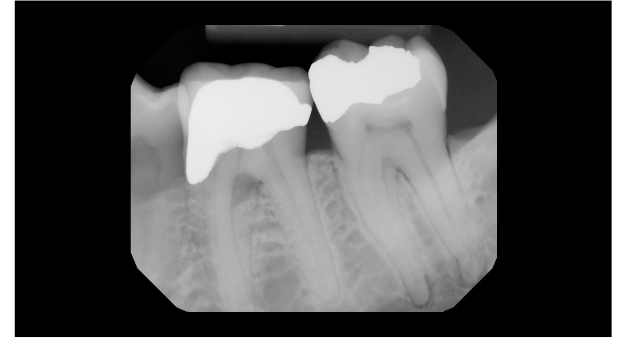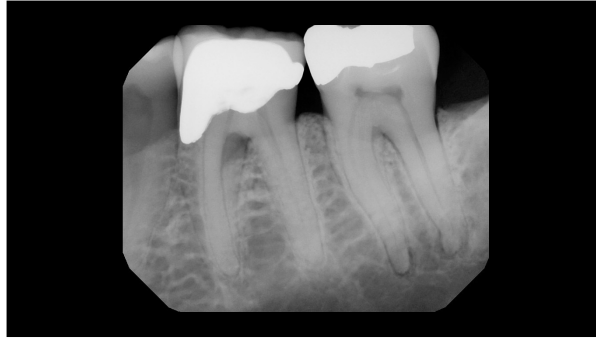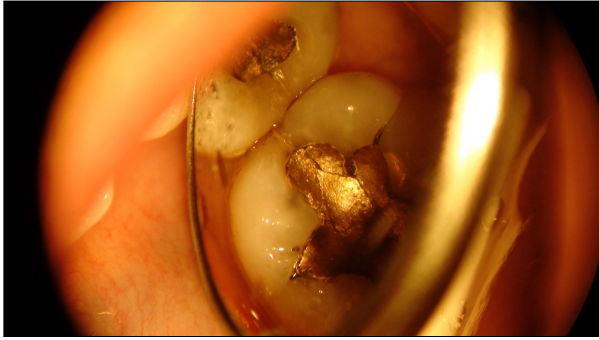
- Remove restoration
- In Dx of necrosis or irreversible pulpitis, access and microscopic examination
- Microscope and transillumination
- Microscope and dye

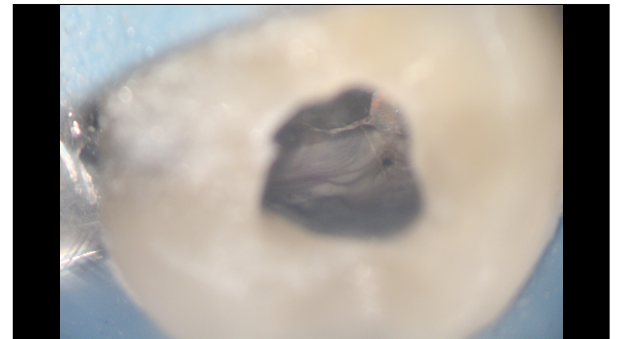
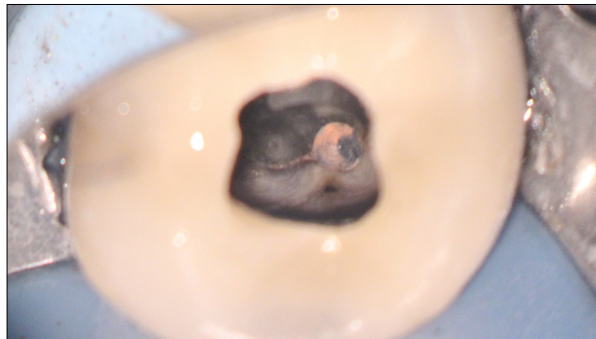
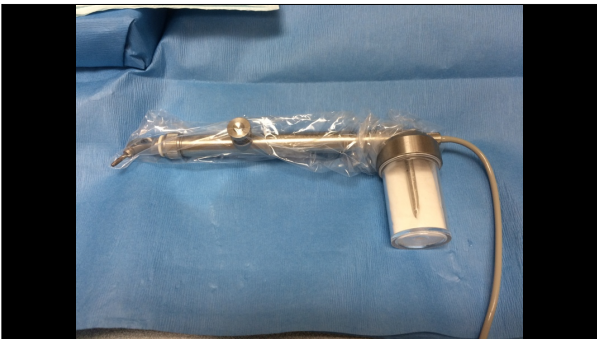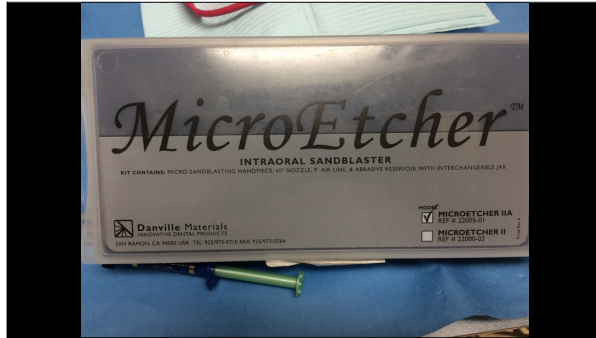
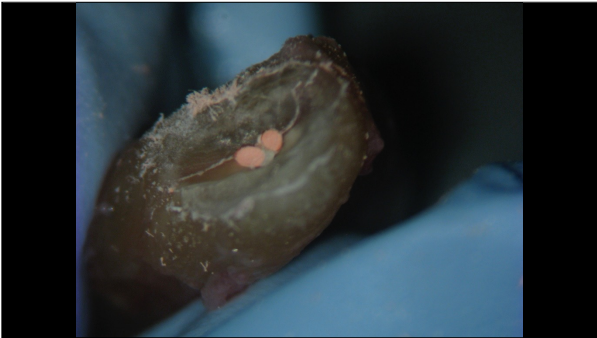
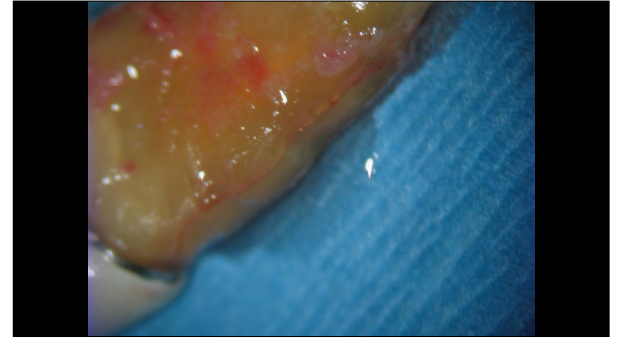
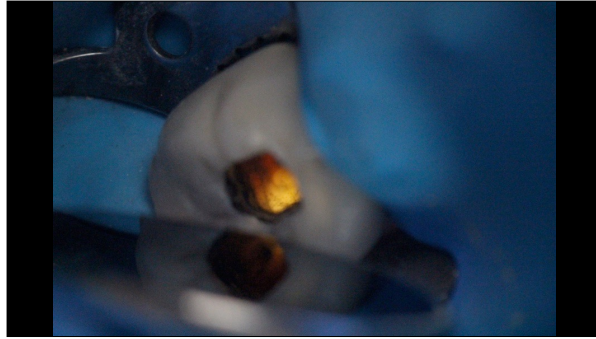
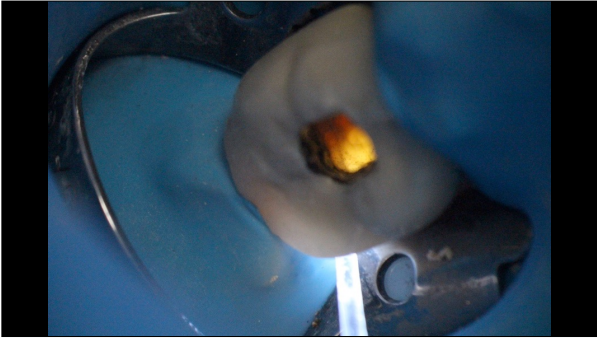


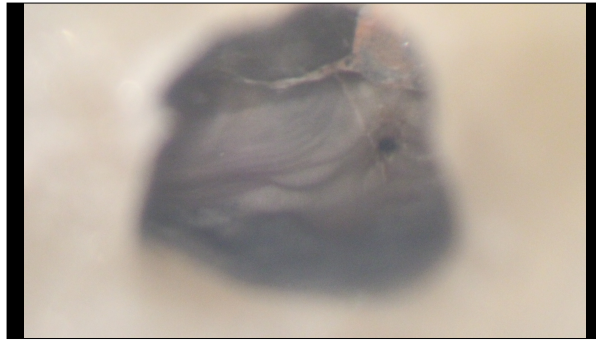
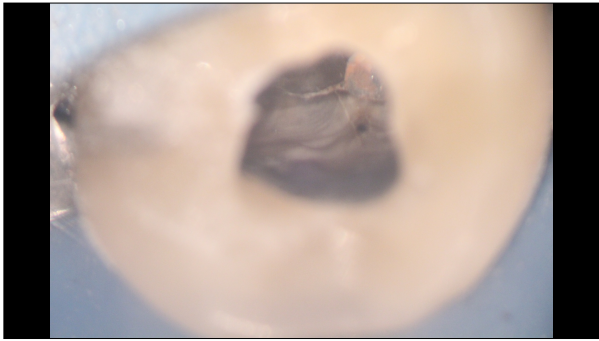
Longitudinal Tooth Fractures

Longitudinal tooth fractures: findings that contribute to complex endodontic diagnoses ERIC M. RIVERA & RICHARD E. WALTON, 2007 16 (1) 84-111 Endodontic Topics





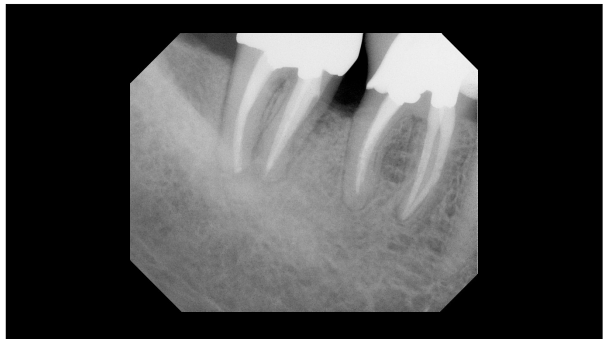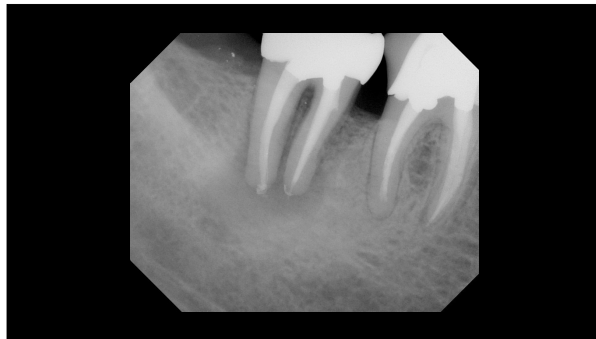
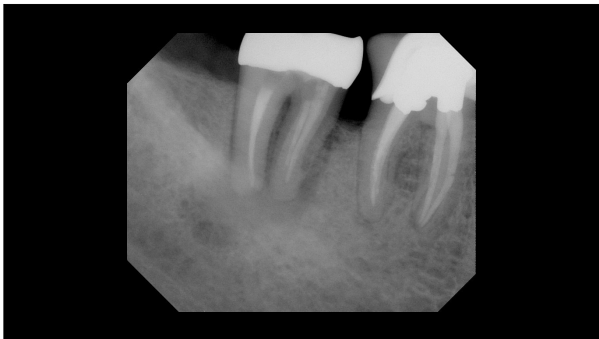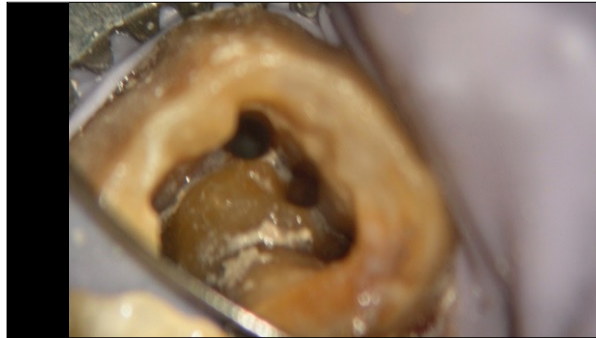


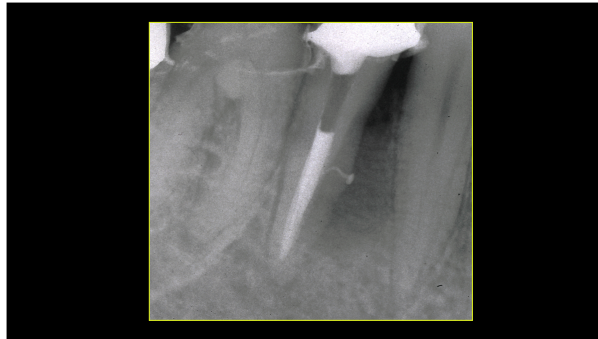
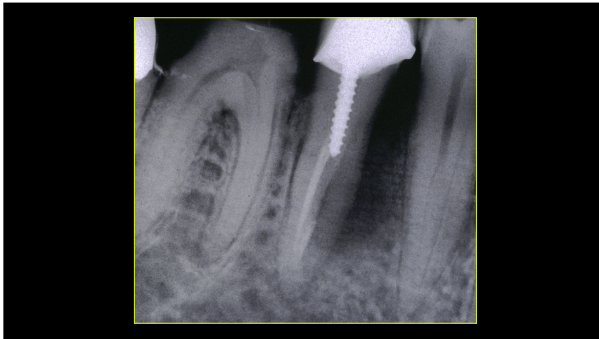


Entities That Mimic Root Fracture

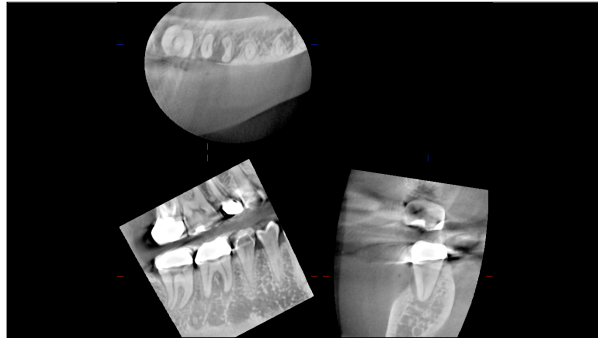
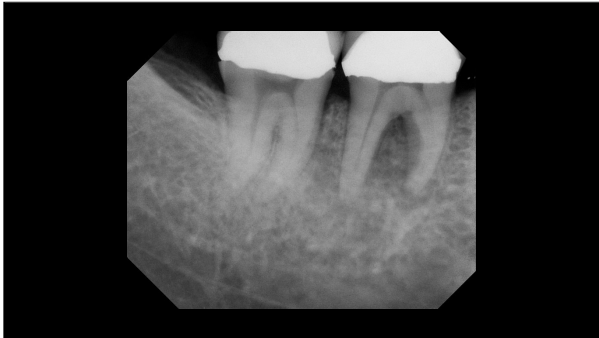Coronal Microleakage

- Gutta Percha susceptible in oral cavity
- Migration of bacteria to apex
- Possible need for retreatment
- Post space contamination
- Prognosis of endo related to coronal restoration



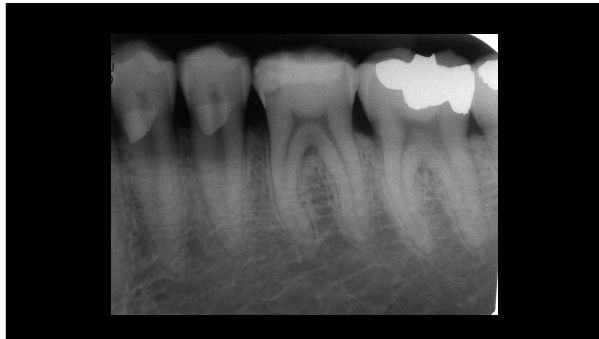
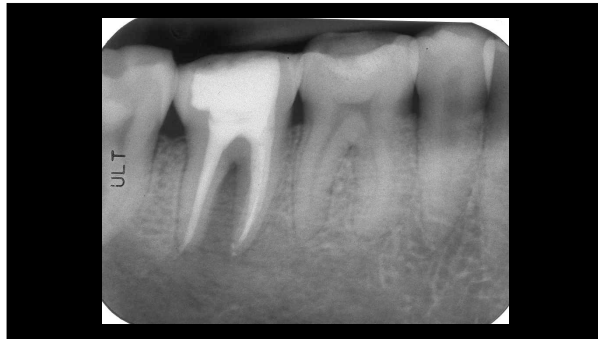
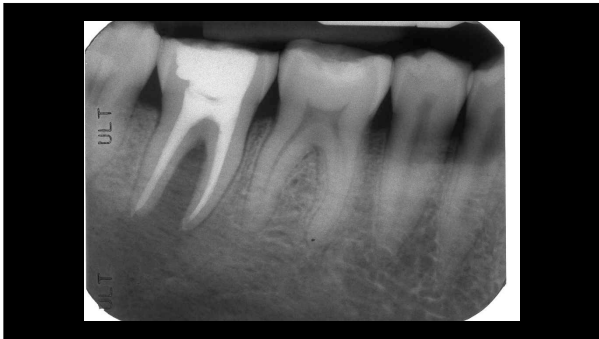Periodontic-Endodontic Lesions



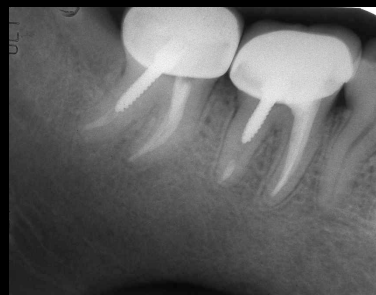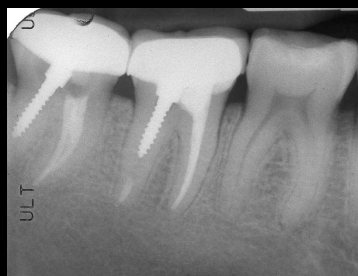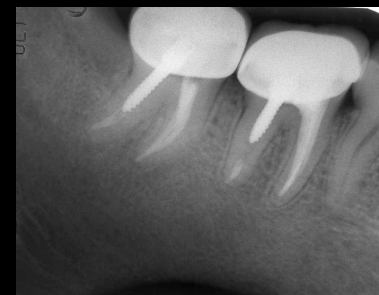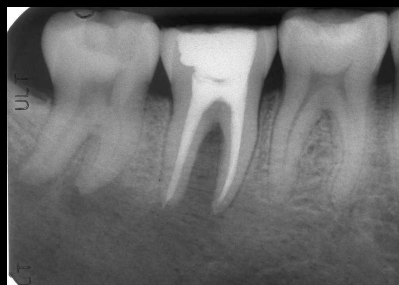History

- CC: "Every now and then my gums swell around this tooth. I have been to several dentists and no one will give me an answer that makes sense. I have been in the middle of two dentists arguing about what to do and I am sick of it."



Pulp Tests

Test	#29	#30	#31	#32
Cold	+	+	-	-
Perc	WNL	WNL	+	+
Palp	WNL	WNL	+	WNL
Perio	<= 3	<=3	9mm B	<=3

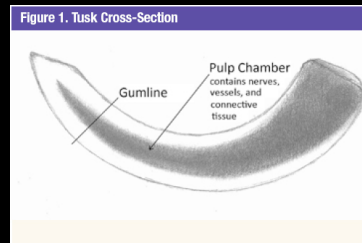


Why Are There So Many Nerves in Teeth?

Importance of Teeth From Evolutionary Standpoint

- Important for nutrition
- Important for defense
- Important for mating

Primary Teeth Are Less Densely Innervated





Loss of Digastric Reflex

- Lack of feedback from stresses on tooth
- Overloading of tooth cyclically
- Overloading of tooth catastrophically

Vital Pulp Therapy

Treatment Outcomes of Mineral Trioxide Aggregate Pulpotomy in Vital Permanent Teeth with Carious Pulp Exposure: The Retrospective Study
Linsuwanont, Pairoj et al.
Journal of Endodontics , February, 2017 , 225 - 230

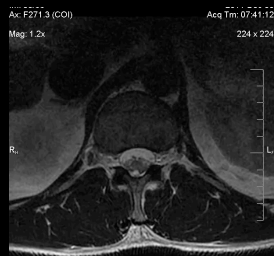
MTA Pulpotomy

- Symptomatic and asymptomatic pulp exposures.
- Rinsed with 2.5% NaOCl
- 3mm of MTA over canal orifices



Treatment Outcomes of Mineral Trioxide Aggregate Pulpotomy in Vital Permanent Teeth with Carious Pulp Exposure: The Retrospective Study
Linsuwanont, Pairoj et al.
Journal of Endodontics , February, 2017 , 225 - 230

Changes in Access

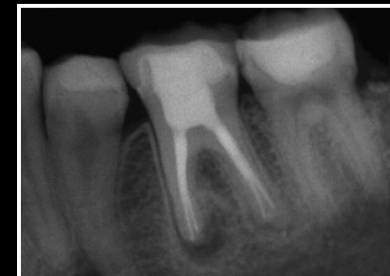

ET: 15
TR: 3560.0
TE: 103.9

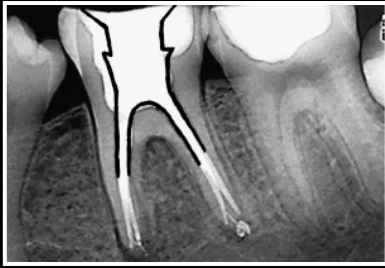Changes in Access Design

- Directed dentin conservation
- Maintain pulp horns
- Preserve a "soffet"
- Opportunistic access to reduce tooth structure removal
- Bank tooth structure

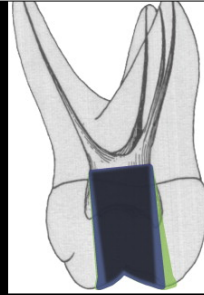
Case Studies in Modern Molar Endodontic Access and Directed Dentin Conservation
David Clark, DDS and John A. Khademi, DDS, MS
Dental Clinics of North America
Volume 54, Issue 2, Pages 285-292 (April 2010)



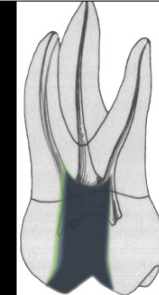
Modern Molar Endodontic Access and Directed Dentin Conservation
David Clark, DDS and John Khademi, DDS, MS
Dental Clinics of North America
Volume 54, Issue 2, Pages 285-292 (April 2010)



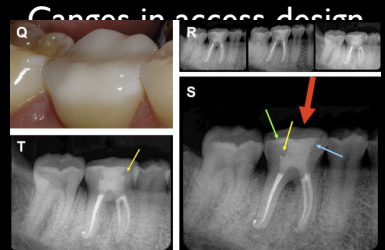
Modern Molar Endodontic Access and Directed Dentin Conservation
 David Clark, DDS and John Khademi, DDS, MS
 Dental Clinics of North America
 Volume 54, Issue 2, Pages 219-223 (April 2010)



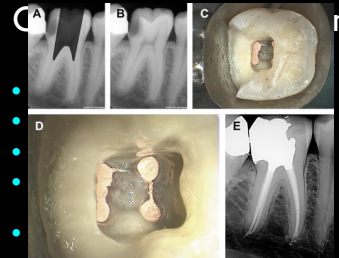
Modern Molar Endodontic Access and Directed Dentin Conservation
 David Clark, DDS and John Khademi, DDS, MS
 Dental Clinics of North America
 Volume 54, Issue 2, Pages 219-223 (April 2010)



Modern Molar Endodontic Access and Directed Dentin Conservation
 David Clark, DDS and John Khademi, DDS, MS
 Dental Clinics of North America
 Volume 54, Issue 2, Pages 219-223 (April 2010)



Case Studies in Modern Molar Endodontic Access and Directed Dentin Conservation
 David Clark, DDS and John A. Khademi, DDS, MS
 Dental Clinics of North America
 Volume 54, Issue 2, Pages 222-228 (April 2010)

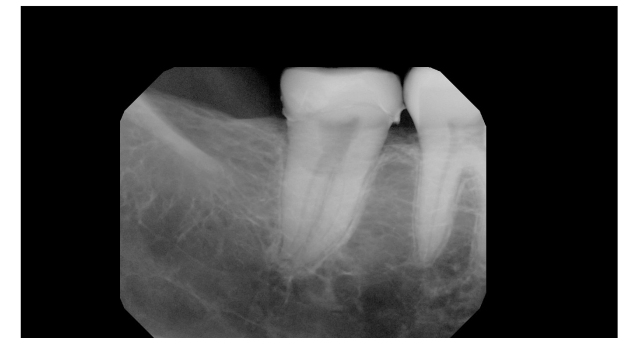
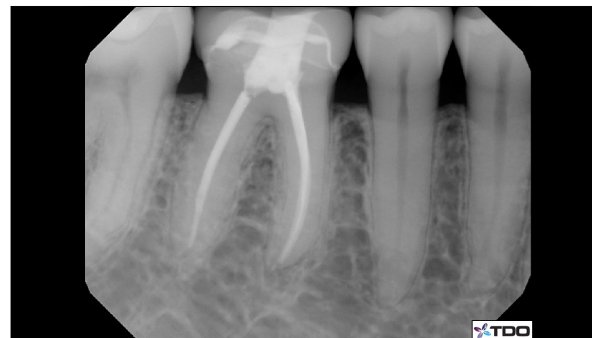
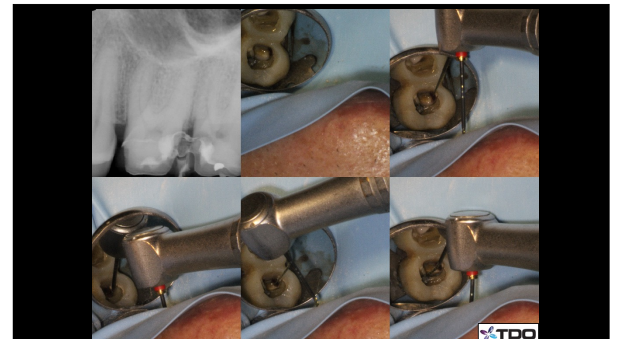
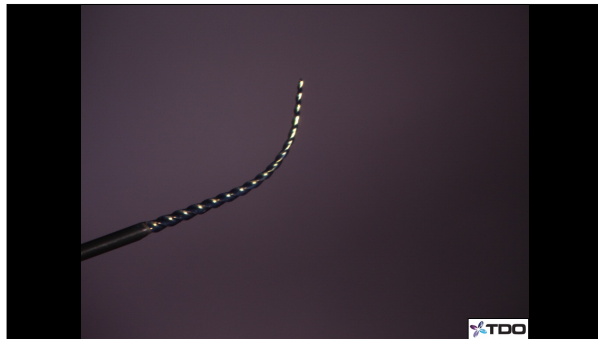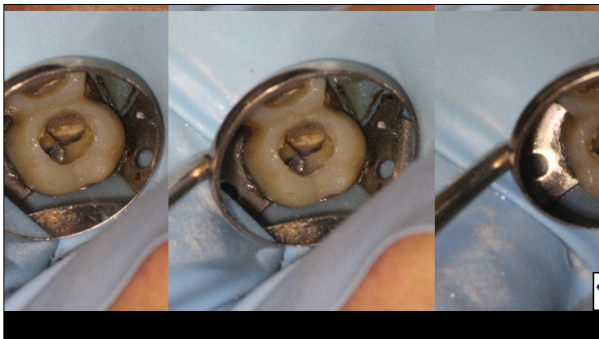
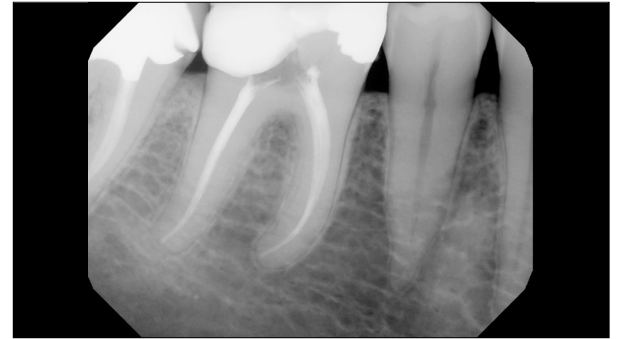
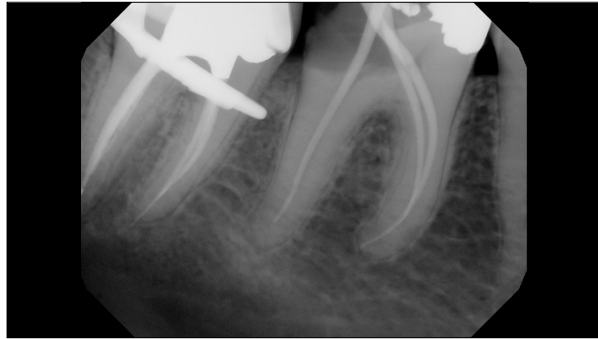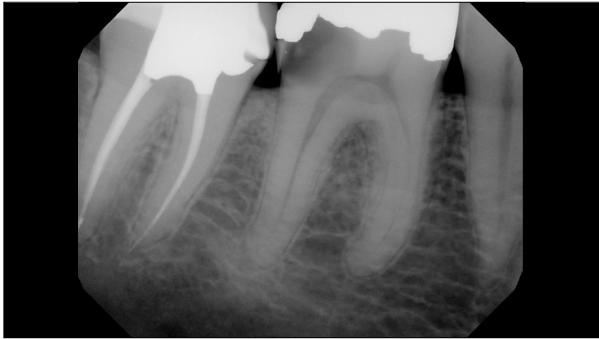
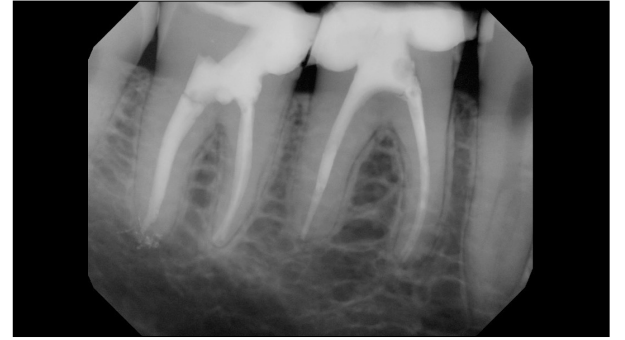
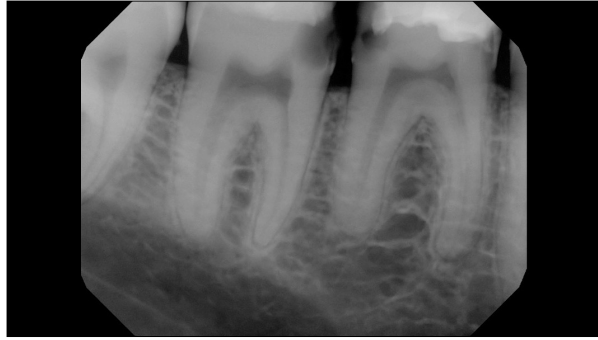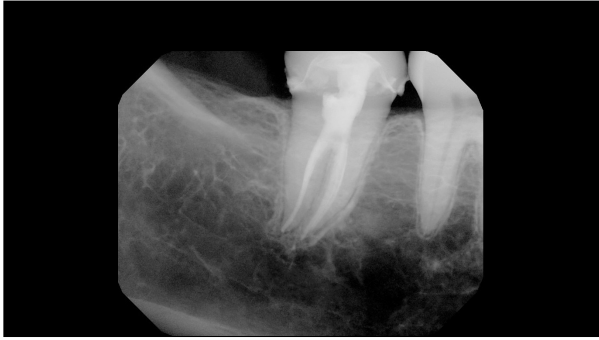
Case Studies in Modern Molar Endodontic Access and Directed Dentin Conservation
 David Clark, DDS and John A. Khademi, DDS, MS
 Dental Clinics of North America
 Volume 54, Issue 2, Pages 222-228 (April 2010)

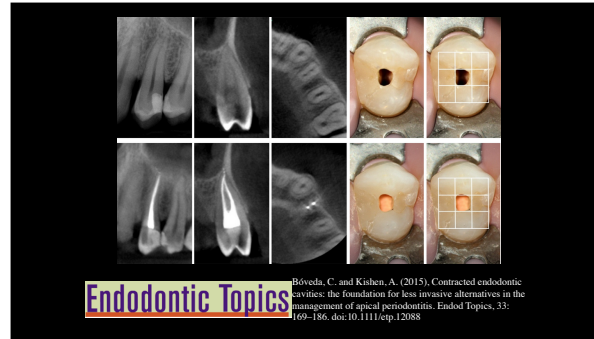
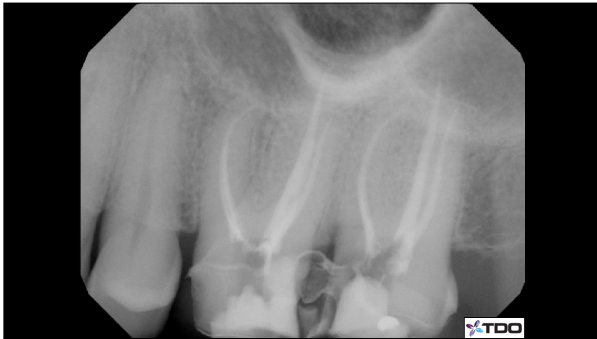
Access and Structural Integrity

- Marginal ridges for B-L function/parafunction
- Pulpal floor for vertical forces

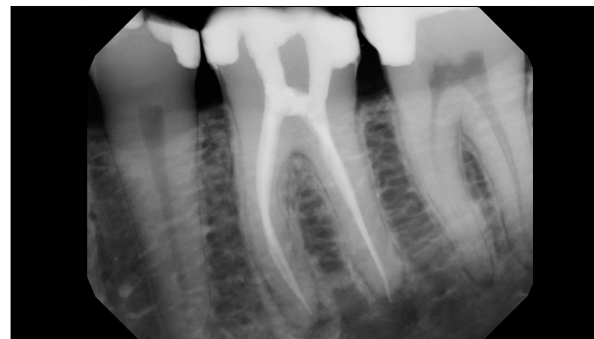
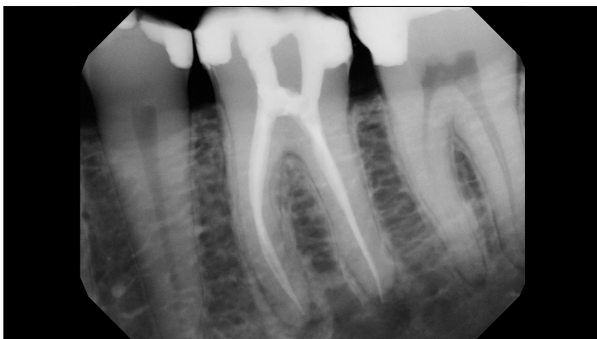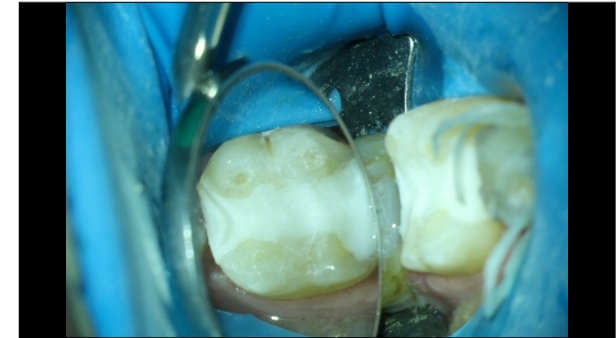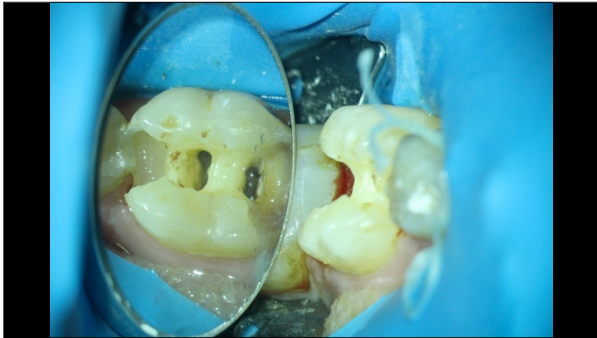Dentin Conservation







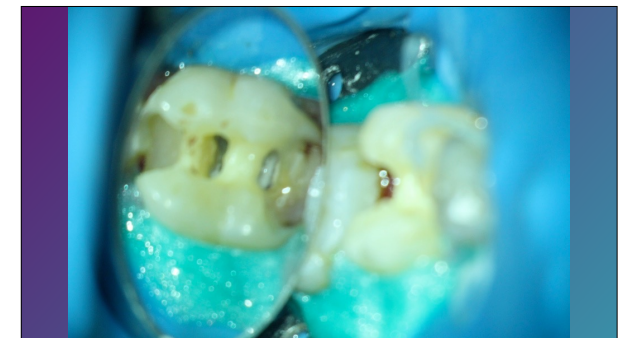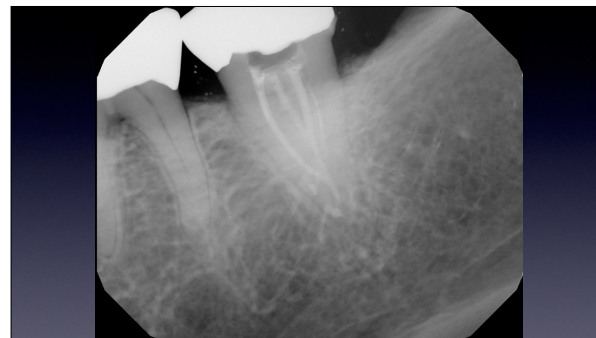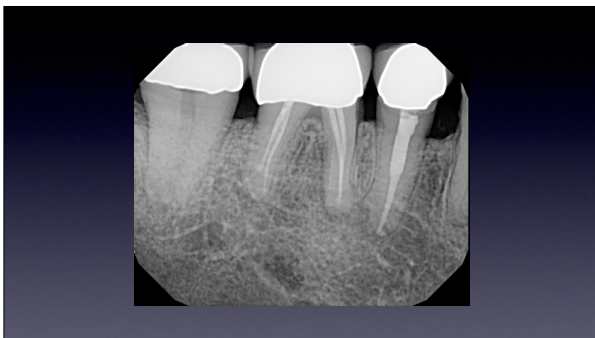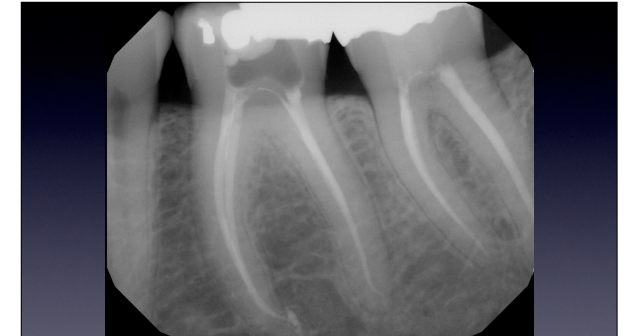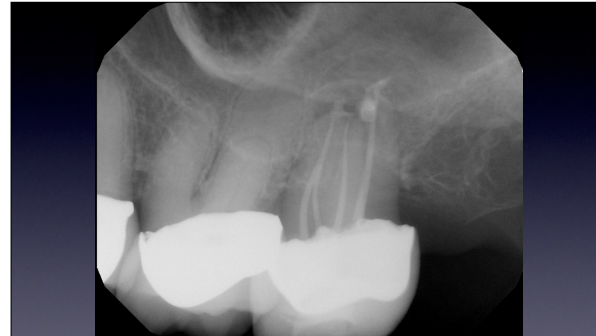

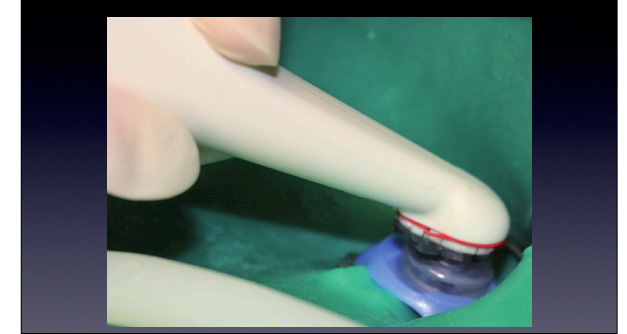
Trussed Access

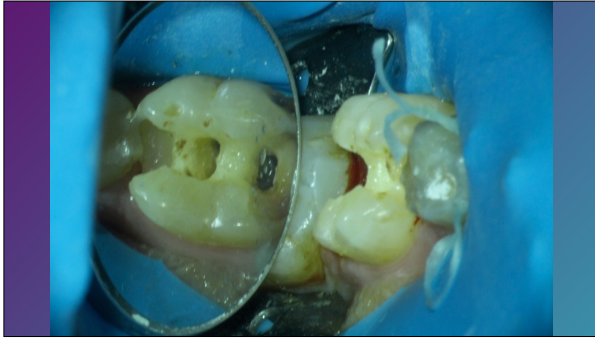

Preserving What Matters

Advances in Irrigation GentleWave

- "Multisonic Ultraclaning"
- Cleans areas not reached by instruments
- Allows for smaller preparations
- Involves creating a platform for treatment device.



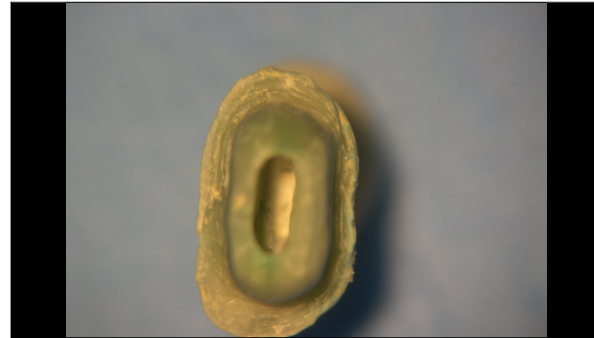



Indications for a Post

- Premolars
- Bulkier than anteriors
- Small pulp chambers
- More likely than molars to receive lateral forces
- Posts required more often than molars

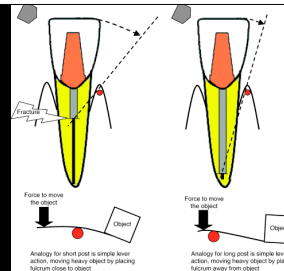
3-D Ferrule

- Vertical: 1.5-2.5mm
- Thickness: 1mm minimum
- TOC: 10° requires 3mm



Principles for Posts

- Retention and resistance
- Failure mode
- Preservation of tooth
- Ferrule effect
- Retrievability





Endodontic Topics
 Mechanisms and risk factors for fracture prediction in endodontically treated teeth
 ANIL KISHEN, 2006: 31 (1) 57-83

Prognosis for Teeth Restored with Posts

- Metal posts: 2% per year. Mean survival of 17 yrs
- 25yr recall cast posts=vital pulp
- Carbon fiber: about 4% per yr

Types of Posts

- Active vs. Passive
- Parallel vs. Tapered
- Prefabricated



Prefabricated Posts

- Usually (in past) metal
- Strong
- Rigid
- Round
- Tapered posts decrease retention, increase remaining dentin
- 8mm of canal length

Custom Cast Post and Cores

- Do not perform as well in in vitro testing
- Two appointments
- Advantageous when multiple teeth need posts
- Small teeth with minimal anti-rotational features
- Temporization?

Ceramic and Zirconium Posts

- Esthetic
- Stiff
- No bond to Zirconium
- Difficult to remove

Fiber Posts



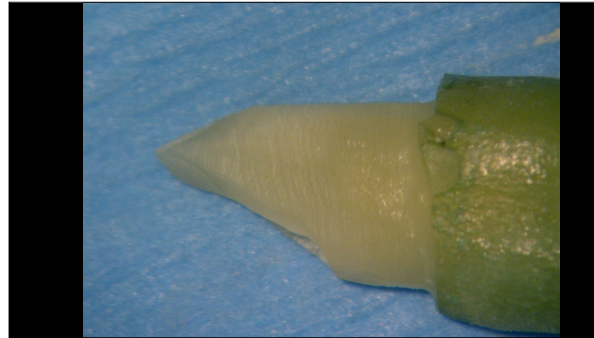

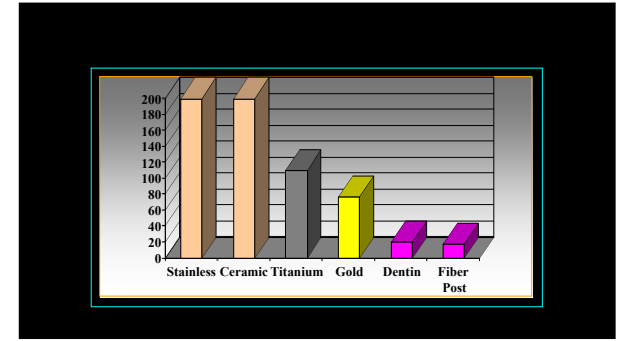
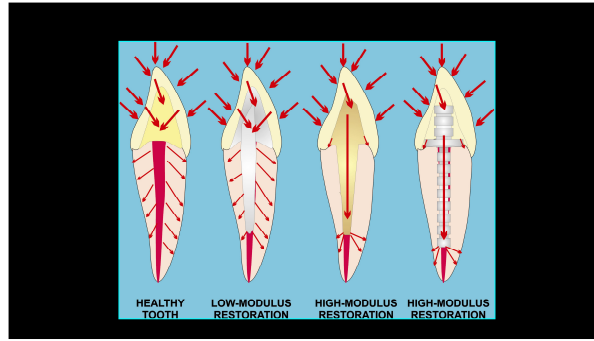

- Carbon, Glass, Silicon, Quartz
- Less Rigid
 - Flexion can lead to leakage
- Esthetic
- Dissipate functional and parafunctional forces
- Failure mode

Choosing an Esthetic Post

- Light transmission to eliminate shadowing
- Bondable within the root canal
- Tapered to minimize tooth removal
- Retentive surface
- Able to absorb and dissipate forces
- Easy removal

Properties of Fiber Reinforced Composite

- Filler materials are carbon, glass, quartz
- Fibers for tensile strength
- Composite for compressive strength
- Some fibers are pre-stressed
- Sandblasting or silane increases strength
- Increasing fiber/matrix increases strength



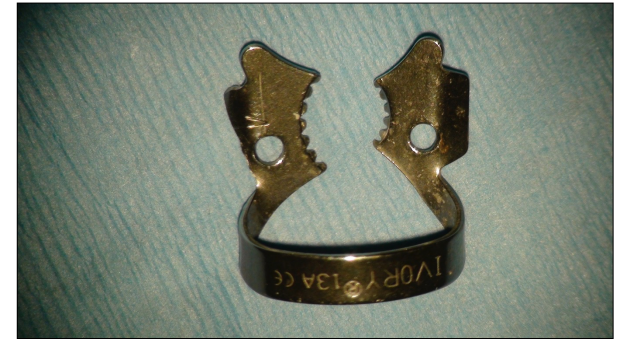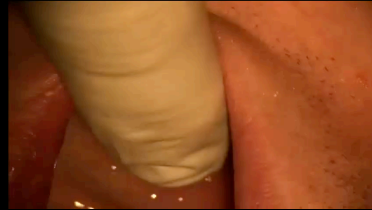Indications for a Post

- Molars
 - All require cuspal coverage
 - Most will not require posts
 - Pulp chamber and canals provide adequate retention for buildup
 - Molars receive vertical forces
 - When indicated posts should be placed in the largest, straightest canal. (Distal in mandibular,

Difficulties Bonding Within the Canal

- C factor
- Difficult to apply uniform primer or adhesive
- Difficult to evaporate volatile solvents
- Compressed air
- Fewer dentinal tubules
- More sclerotic dentin

Post Placement is Endodontics



Resin Cements

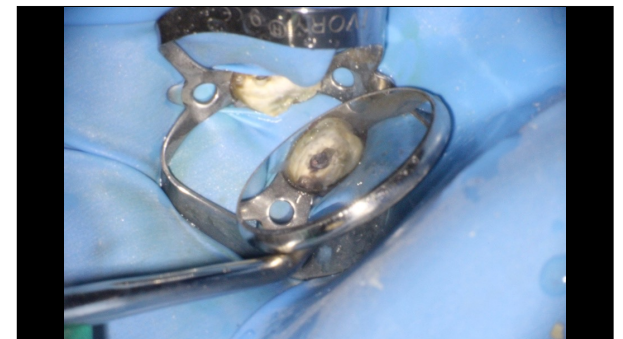
- Increased retention
- Less Leakage
- Short term strengthening of roots
- Eugenol?
- Technique sensitive
- Auto cure place with post

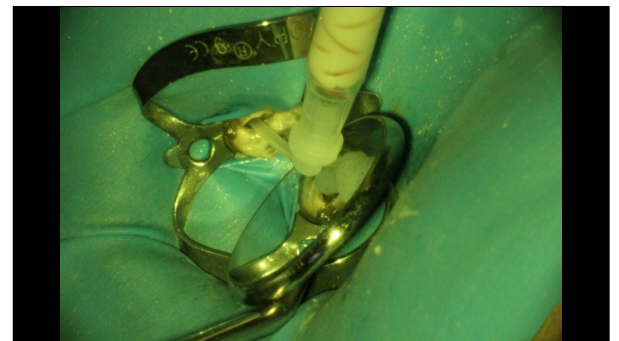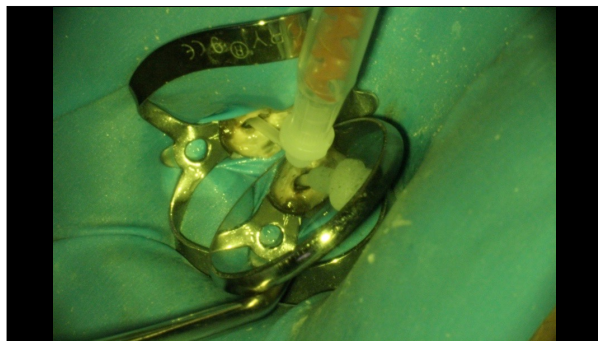
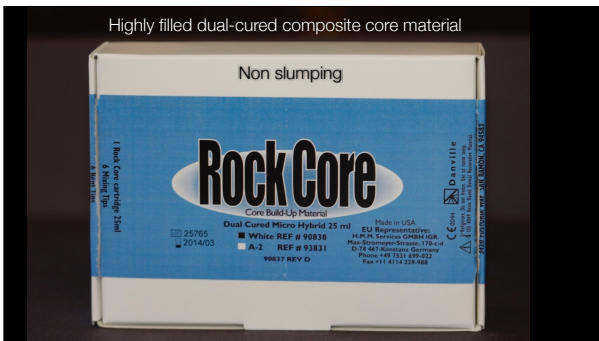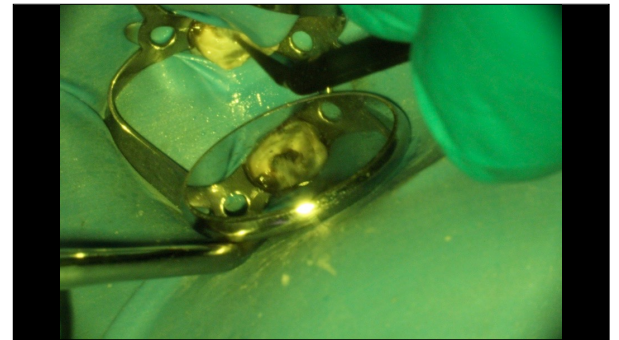
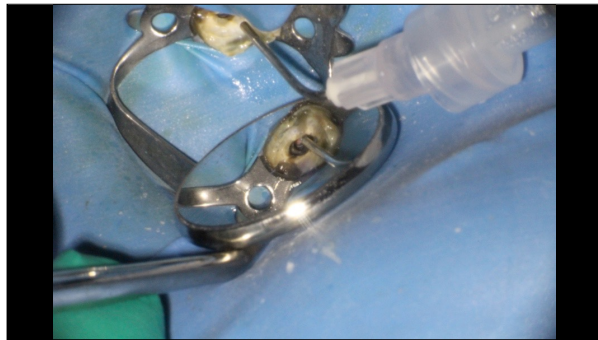
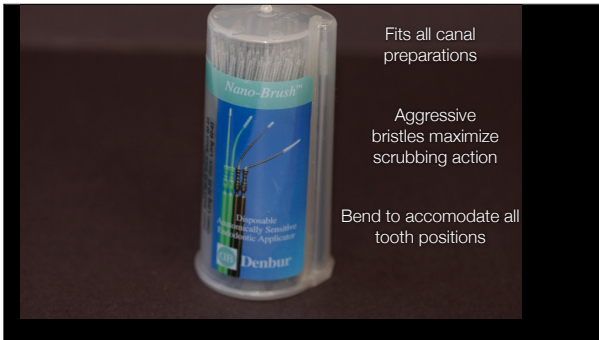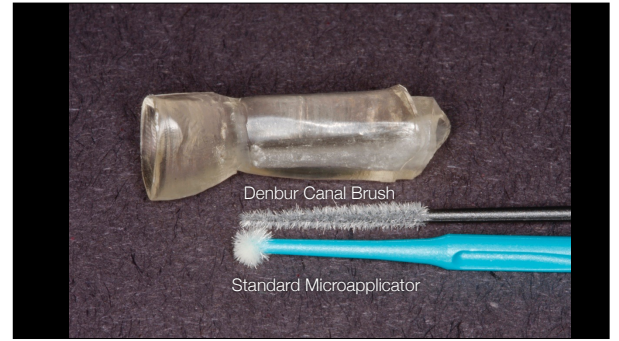
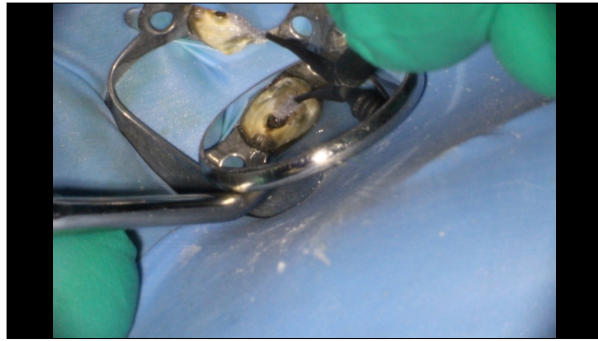
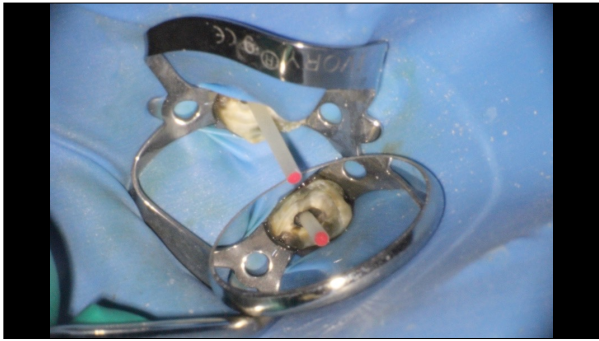Eugenol Effects

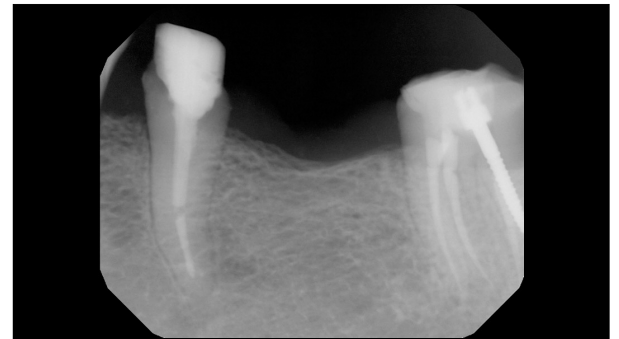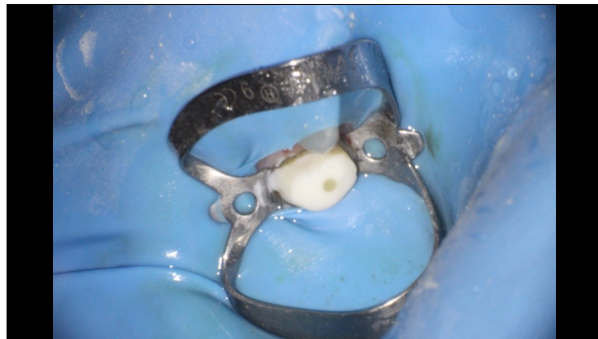
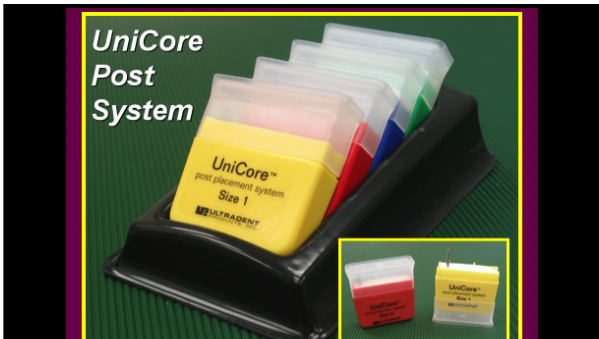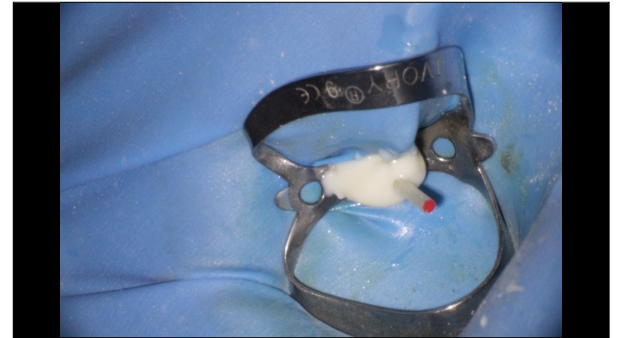
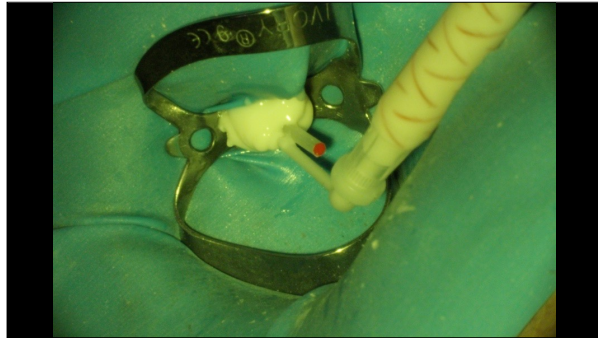
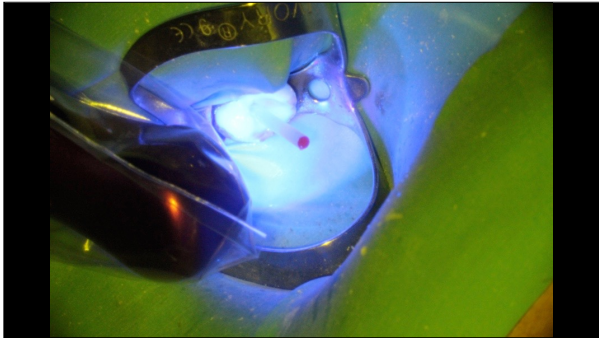
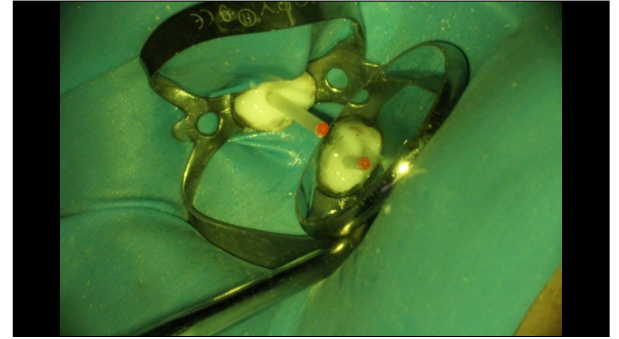
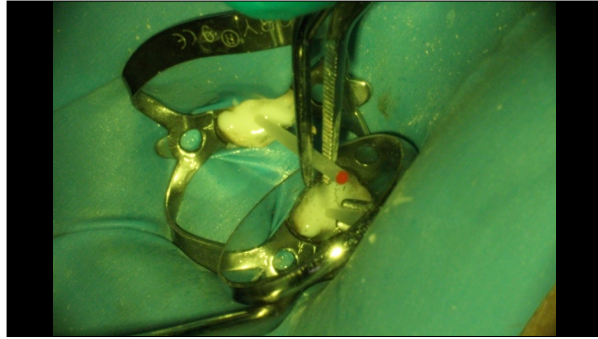
- Decreases polymerization
- Can be eliminated with ethanol
- Can be eliminated with 10%, then 37% phosphoric acid
- Possible indication for etch and rinse adhesive system

NaOCl Effects

- Increased O_2 at dentin surface
- Can be reversed by sodium ascorbate
- Can be reversed by finishing bur







Long-term Performance of Fiber Posts

- 985 fiber posts in clinical patients
- Monitored for 7-11 yrs
- 89-93% survival
- 1 root fracture

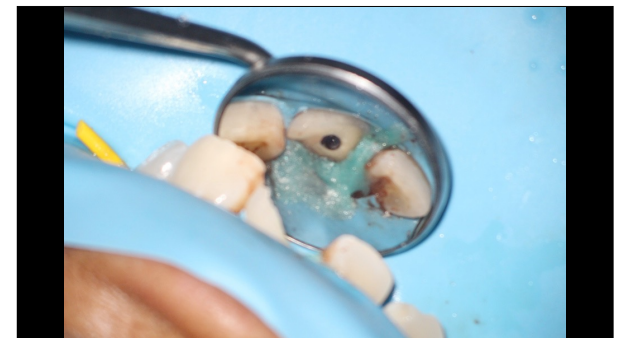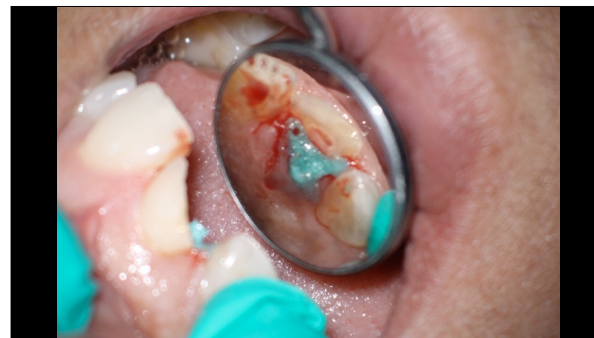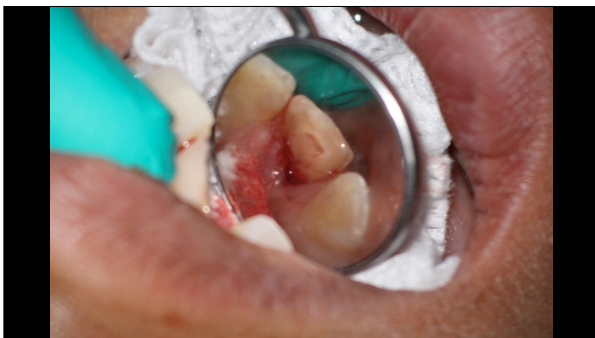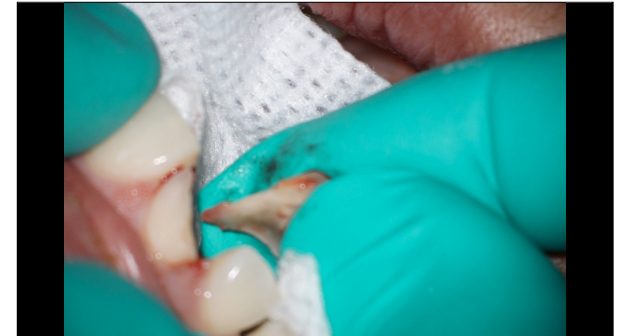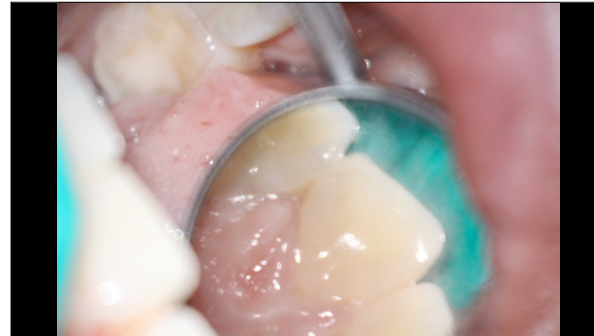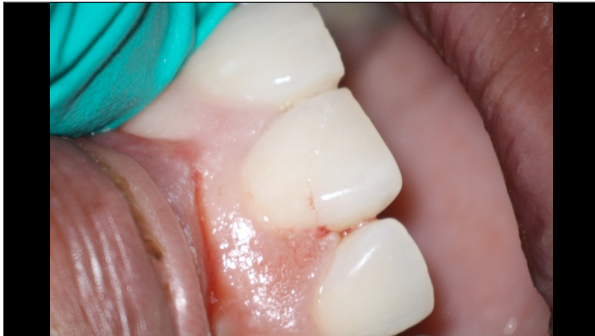Ferrare et al. *Am J Dent* 2007; 20:287-291


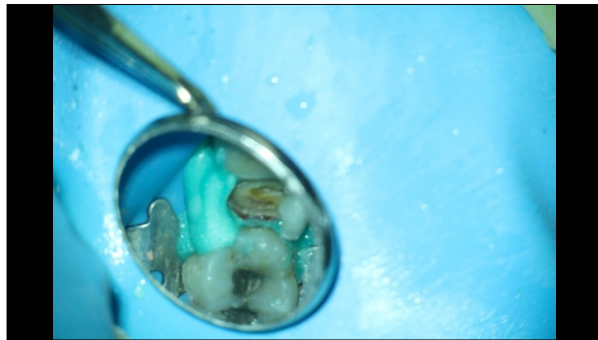
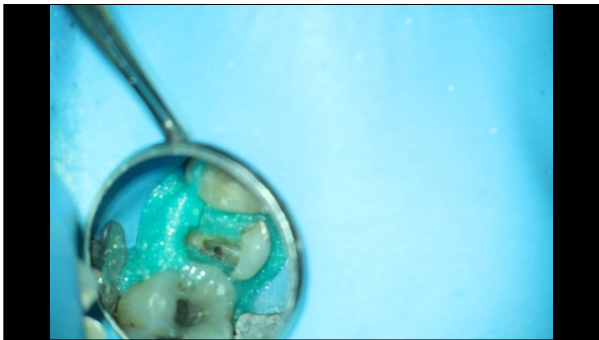
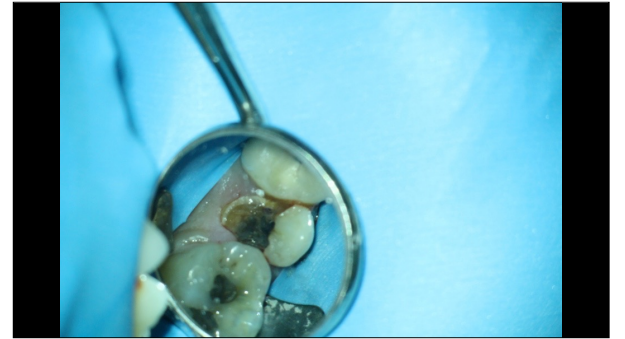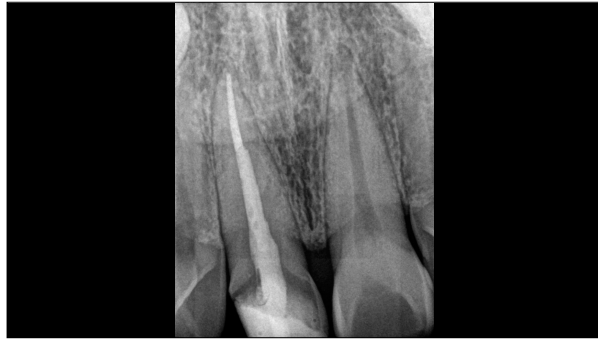
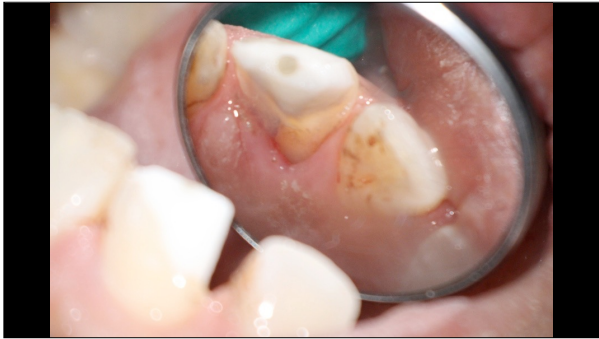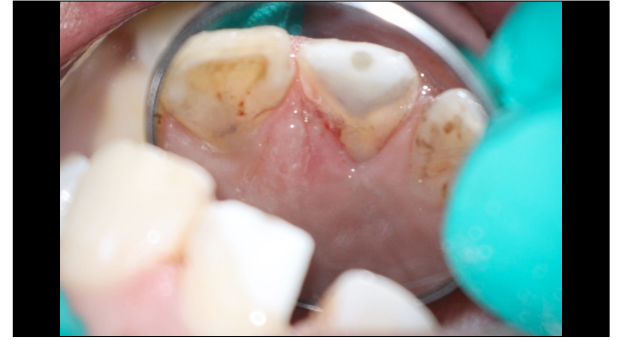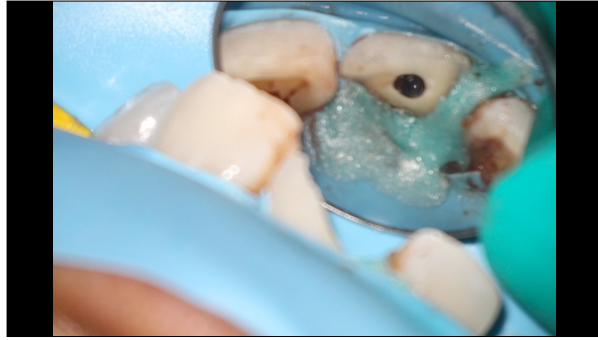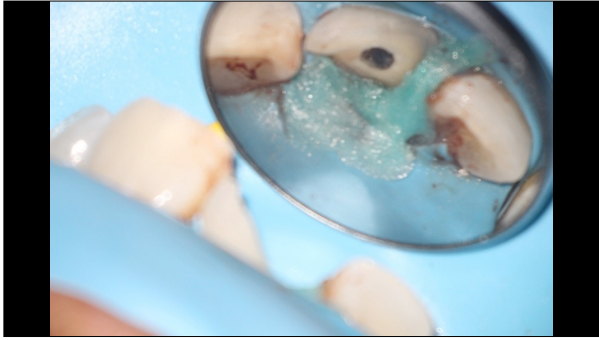Biological and Technical Complications with Respect to Presence/Absence of a Fiber Post

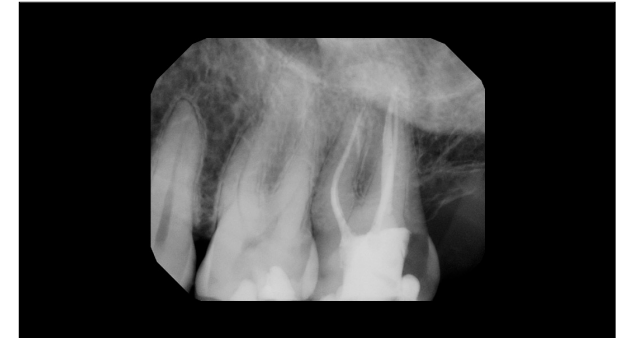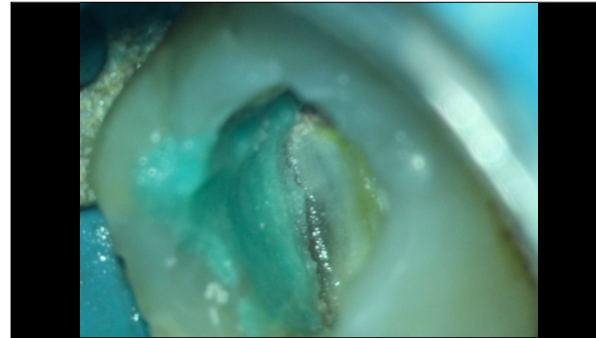
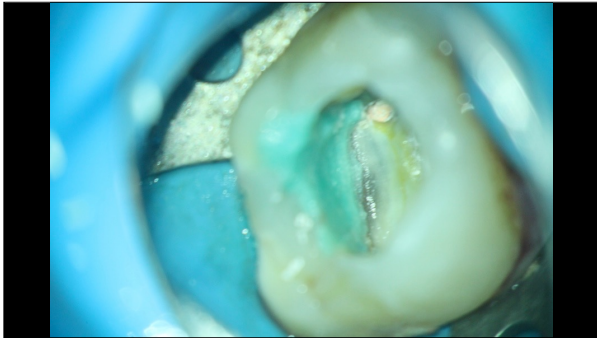
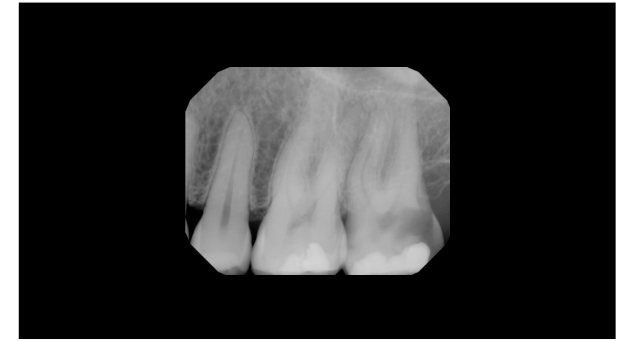
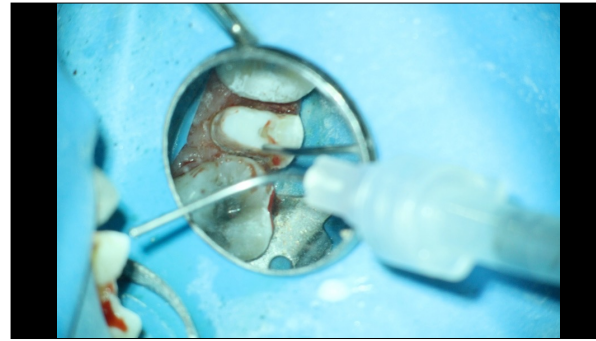
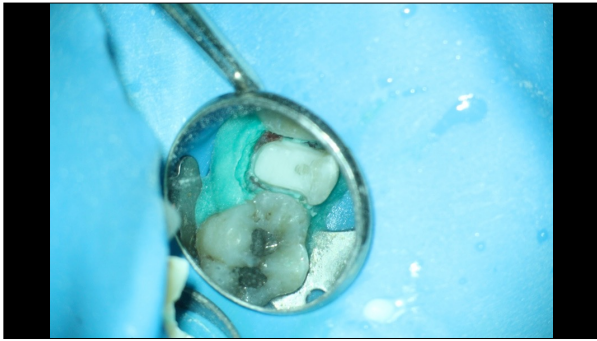
	Fiber post, n (%) n = 106/144 (73.6%)		No fiber post, n (%) n = 38/144 (26.4%)		Total, n (%) N = 144 (100%)
	Tooth loss	No tooth loss	Tooth loss	No tooth loss	
Endodontic failure	0 (0)	2 (1.9)	0 (0)	2 (5.3)	4 (2.7)
Recurrent caries/periodontitis	0 (0)	1 (0.9)	0 (0)	2 (5.3)	3 (2.1)
Abutment fracture	0 (0)	0 (0)	1 (2.6)	0 (0)	1 (0.7)
Loss of retention	0 (0)	0 (0)	0 (0)	0 (0)	0 (0)
Vertical root fracture	6 (5.7)	6 (5.7)	8 (21.1)	1 (2.6)	21 (14.6)
Post fracture	0 (0)	0 (0)	0 (0)	0 (0)	0 (0)
Total	6 (5.7)	9 (8.5)	9 (23.7)	5 (13.2)	29 (20.1)



Long-term Clinical Outcomes of Endodontically Treated Teeth Restored with or without Fiber Post-retained Single-unit Restorations
Guldener, Kevin A., et al.
Journal of Endodontics, February, 2017, 188 - 193

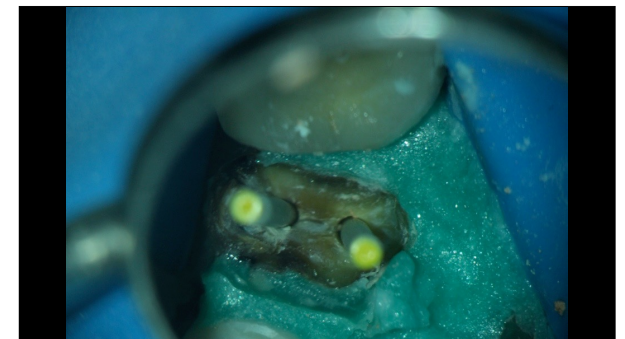
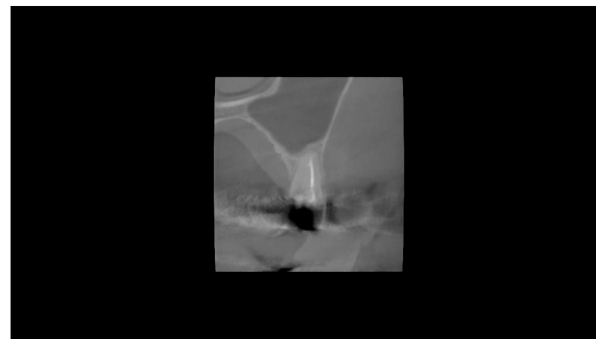


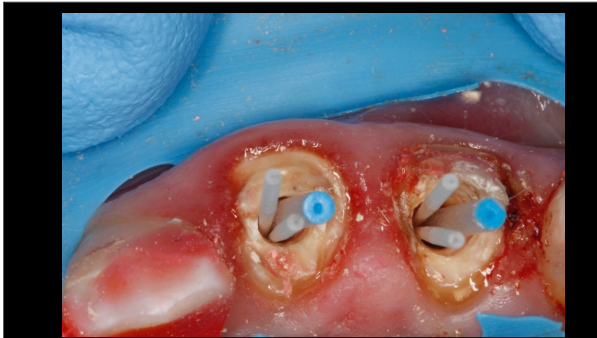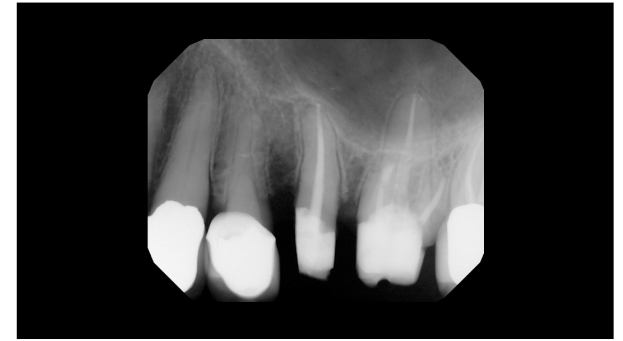
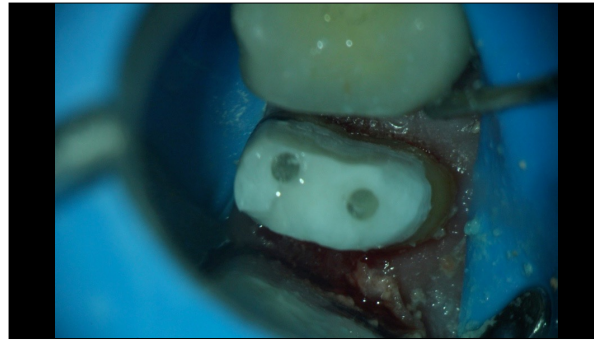
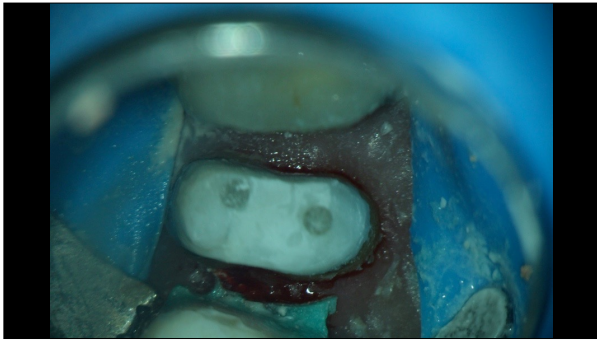




Multiple Post Technique

- Ideal for ovoid canals
- Can rebuild arch
- Macro-mechanical retention
- Bonded monoblock





Is It Good to Have the Same Modulus of Elasticity as Dentin?

- Better stress distribution
- Movement of the core?
- Post is thinner than root therefore need stiffer material

Do Bonded Posts Really Strengthen Roots?

- Yes
- Effect may be lost with time
- Lab tests need to incorporate cyclic loading

Accessing Through Restorations

- Accessing through restorations decreases retention
- Restoring the access cavity regains retention
- Placing a post further increases retention
- A bonded fiber post may increase fracture resistance